Immunology and Microbiology

Murine Model of Primary Acquired Ocular Toxoplasmosis: Fluorescein Angiography and Multiplex Immune Mediator Profiles in the Aqueous Humor

Kexin Li, Xue Feng, Kenji Hikosaka, and Kazumi Norose

Department of Infection and Host Defense, Graduate School of Medicine, Chiba University, Inohana, Chuo-ku, Chiba, Japan

Correspondence: Kazumi Norose, Department of Infection and Host Defense, Graduate School of Medicine, Chiba University, 1-8-1 Inohana, Chuo-ku, Chiba 260-8670, Japan; norose@faculty.chiba-u.jp.

Received: July 21, 2020
Accepted: February 6, 2021
Published: March 8, 2021

Citation: Li K, Feng X, Hikosaka K, Norose K. Murine model of primary acquired ocular toxoplasmosis: Fluorescein angiography and multiplex immune mediator profiles in the aqueous humor. *Invest Ophthalmol Vis Sci.* 2021;62(3):9. https://doi.org/10.1167/iovs.62.3.9

Purpose. To establish a murine model of primary acquired ocular toxoplasmosis (OT) and to investigate the immune mediator profiles in the aqueous humor (AH).

Methods. C57BL/6 mice were perorally infected with *Toxoplasma gondii*. The ocular fundus was observed, and fluorescein angiography (FA) was performed. The AH, cerebrospinal fluid (CSF), and serum were collected before infection and at 28 days postinfection (dpi); the immune mediator levels in these samples were analyzed using multiplex bead assay.

Results. Fundus imaging revealed soft retinochoroidal lesions at 14 dpi; many of these lesions became harder by 28 dpi. FA abnormalities, such as leakage from retinal vessels and dilation and tortuosity of the retinal veins, were observed at 14 dpi. Nearly all these abnormalities resolved spontaneously at 28 dpi. In the AH, interferon-γ, interleukin (IL)-1α, IL-1β, IL-6, IL-10, IL-12(p40), IL-12(p70), CCL2/MCP-1, CCL3/MIP-1α, CCL4/MIP-1β, CCL5/RANTES, and CXCL1/KC levels increased after infection. All these molecules except IL-1α, IL-4, and IL-13 showed almost the same postinfection patterns in the CSF as they did in the AH. The tumor necrosis factor α, IL-4, and IL-5 levels in the AH and CSF of the *T. gondii*–infected mice were lower than those in the serum. The postinfection IL-1α, IL-6, CCL2/MCP-1, CCL4/MIP-1β, and granulocyte colony-stimulating factor levels in the AH were significantly higher than those in the CSF and serum.

Conclusions. A murine model of primary acquired OT induced via the natural infection route was established. This OT model allows detailed ophthalmologic, histopathologic, and immunologic evaluations of human OT. Investigation of AH immune modulators provides new insight into OT immunopathogenesis.

Keywords: *Toxoplasma gondii*, cytokine, chemokine, aqueous humor, cerebral spinal fluid

An intracellular protozoan parasite, Toxoplasma gondii, can be acquired by ingesting undercooked food or water contaminated with tissue cysts or oocysts or via maternal/fetal transmission, organ transplantation, or an accident.[1,2] This parasite preferentially infects the eyes and brain, leading to ocular toxoplasmosis (OT) and toxoplasmic encephalitis (TE), respectively.[1,2] OT is a major cause of posterior uveitis, which can result in blindness, and TE causes brain abscesses, which can be lethal.[1,2]

Old retinal scars are hallmarks of OT, and the presence of pigmented old scars near the active lesion in the retina strongly suggests that an active lesion is from a congenital infection recurrence. However, OT is known to develop not only from recurrences of congenital infection but also from postnatally acquired primary infections,[3–8] which account for the majority of OT cases.[4,9,10] Additionally, evidence of OT followed by an outbreak of toxoplasmosis, that is, the detection of both immunoglobulin (Ig) G and IgM, has confirmed that primary acquired OT may be more frequent than previously thought.[11–15]

The eyes, like the brain, possess inherent immune privilege, so immune responses to *T. gondii* infection in the eyes might differ from those in other systemic organs. Immune reactions to *T. gondii* infection are associated with a T-helper 1 (Th1) response, defined by interleukin (IL)-12 and interferon (IFN)-γ production.[16,17] Immune system–related factors have been under scrutiny for their roles in toxoplasmosis.[16–20] Although TE has been actively investigated in both humans and mice,[21–27] the immunopathogenic mechanisms of OT are complex and remain incompletely understood.

Because uveitis can be caused by various infectious pathogens, including *T. gondii*, as well as by noninfectious diseases, it is difficult to accurately diagnose the underlying cause of uveitis. Particularly in atypical cases or when high vitreous opacity prevents examination of the ocular fundus, ophthalmic findings alone are insufficient to differentiate OT from other ocular inflammatory disorders. To prevent ocular tissue damage and adverse visual outcomes, early diagnosis and treatment are necessary. Although OT diagnosis can

Copyright 2021 The Authors

This work is licensed under a Creative Commons Attribution-NonCommercial-NoDerivatives 4.0 International License.

Downloaded from abstracts.iovs.org on 04/26/2024

be confirmed on the basis of responsiveness to specific treatment or results from biological or polymerase chain reaction assays,[1,2,28] these approaches are time consuming, expensive, and insufficiently sensitive.[29,30]

Recently, analysis of immune mediator profiles in the aqueous humor (AH) has been reported as useful in confirming not only OT diagnosis and stage differences but also uveitis reactivation.[31–35] Analysis of these AH profiles may provide direct insight into the immunopathogenesis underlying uveitis-induced retinal damage. However, there are few reports concerning such molecules in the AH of OT patients, and these details remain unknown.[36–44]

Although there are anatomic, biochemical, and immunological differences between mice and humans, a murine model of OT can provide key information about human OT[6] and would expedite an exact evaluation of the immunopathogenesis of this disease. Some active experimental murine research on immune profiles in the AH of OT has been performed via intravitreal or peritoneal injections of the parasite, which are unnatural infection routes.[41,45–48] However, knowledge about immune profiles in the AH during OT from a natural infection route is lacking.

The present study aimed to establish a murine model of primary acquired OT induced via the natural infection route and to clarify primary acquired OT-specific immunopathogenesis via comparisons of postinfection immune mediator levels among the AH, cerebrospinal fluid (CSF), and serum. Experimental animal models of OT will contribute not only to the understanding of the immunopathogenesis of human OT but also to the clinical use of the AH immune mediator profile as a diagnostic tool for various types of uveitis.

Methods

Parasites, Mice, and Toxoplasmosis Induction

We adhered to the guidelines established in the ARVO Statements for the Use of Animals in Ophthalmic and Vision Research. The experiments were approved by the Ethics Committee of Graduate School of Medicine, Chiba University (project no. A28-261). The cysts of an avirulent *T. gondii* strain, Fukaya (type II), were obtained from the brains of C57BL/6 mice (susceptible strain) previously infected perorally. Inbred male C57BL/6 mice were purchased from SLC Co. (Hamamatsu, Japan) and used at age 12 to 16 weeks old. All mice had normal findings on physical and ophthalmic examinations and had no detectable serum antibodies directed against *T. gondii* before infection. The mice were infected perorally with 10 cysts of *T. gondii* on day 0.[49] Normal, uninfected mice were used as controls.

Ophthalmic Examinations

The ocular fundus was observed before infection and at 7, 14, and 28 days post-infection (dpi) using a fundus camera (Kowa's Genesis-Df Handheld, Kowa, Nagoya, Japan) and fluorescein angiography (FA) was performed as described previously[50] before infection and at 14 and 28 dpi in conscious mice.

Histopathology and Immunohistochemistry

At 28 dpi, the mice were exsanguinated while under deep anesthesia with pentobarbital, then perfused with phosphate-buffered saline solution. Their eyes and brain were isolated, fixed in 12% buffered formalin, embedded in paraffin, and stained with hematoxylin and eosin.[49] Images were acquired on a light microscope (BX41; Olympus, Tokyo, Japan) equipped with a charge-coupled device camera (FX630; Olympus).

For immunohistochemical analysis, eyes were embedded directly in O.C.T. compound (Tissue-Tek, Torrance, CA, USA) and flash frozen. Sections (5 µm thick) were cut on a cryostat (CM1510S; Leica, Nussloch, Germany), fixed in 75% acetone and 25% EtOH, and stained using a polyclonal rabbit anti-*T. gondii* antibody with an Alexa Fluor 488–conjugated goat anti-rabbit antibody (Molecular Probes; Invitrogen, Carlsbad, CA, USA) as a secondary antibody.[19] Rhodamine-labeled *Dolichos biflorus* agglutinin (Vector Laboratories, Burlingame, CA, USA) was used to visualize the cyst wall.[19] Cell nuclei were stained with DAPI (Invitrogen). Images were acquired on a fluorescence microscope (IX71, Olympus) equipped with a charge-coupled device camera (QImaging QIClick; Nippon Roper, Tokyo, Japan). The images were processed with imaging software (QCapture Pro 7.0, Nippon Roper).

Immune Mediator Assays

At 0 dpi and 28 dpi, blood, AH, and CSF samples were collected. Blood was taken from the left ventricles; the mice, while under deep anesthesia with pentobarbital, were then perfused with cold phosphate-buffered saline solution to remove the whole blood. Serum was collected via centrifugation of the clotted blood. The AH was collected using a 30-gauge needle inserted at the limbus. The CSF was collected from the cisterna magna.[51] These samples were pooled and stored at −80°C until analysis. Each experimental group was composed of six animals (12 eyes), and each experiment was performed three times.

The Bio-Plex Pro Mouse Cytokine 23-plex Assay (Bio-Rad, Tokyo, Japan) was used for the analysis of the following immune mediators in accordance with the manufacturer's recommendations: IFN-γ, IL-1α, IL-1β, IL-2, IL-3, IL-4, IL-5, IL-6, IL-9, IL-10, IL-12(p40), IL-12(p70), IL-13, IL-17A, tumor necrosis factor α (TNF-α), CCL2/MCP-1 (monocyte chemotactic protein-1), CCL3/MIP-1α (macrophage inflammatory protein-1α), CCL4/MIP-1β (macrophage inflammatory protein-1β), CCL5/RANTES (regulated on activation, normal T-cell expressed and secreted), CCL11/eotaxin, CXCL1/KC (IL-8 homologue keratinocyte-derived chemokine), granulocyte colony-stimulating factor (G-CSF), and granulocyte-macrophage colony-stimulating factor (GM-CSF). The data were analyzed with the Bio-Plex Manager software V1.1 (Bio-Rad).

Statistics

The values shown are the means ± SD of three independent experiments. The level differences between the uninfected and infected groups for each target molecule were evaluated using Student's *t*-test. The level differences between the AH and CSF, AH and serum, and CSF and serum for the target molecules were evaluated with an ANOVA followed by a post hoc Tukey–Kramer test. A P value <0.05 was considered significant. All statistical analyses were performed using Statcel for Excel, 4th ed (OMS Publishing Co., Tokyo, Japan).

Investigative Ophthalmology & Visual Science

Downloaded from abstracts.iovs.org on 04/26/2024

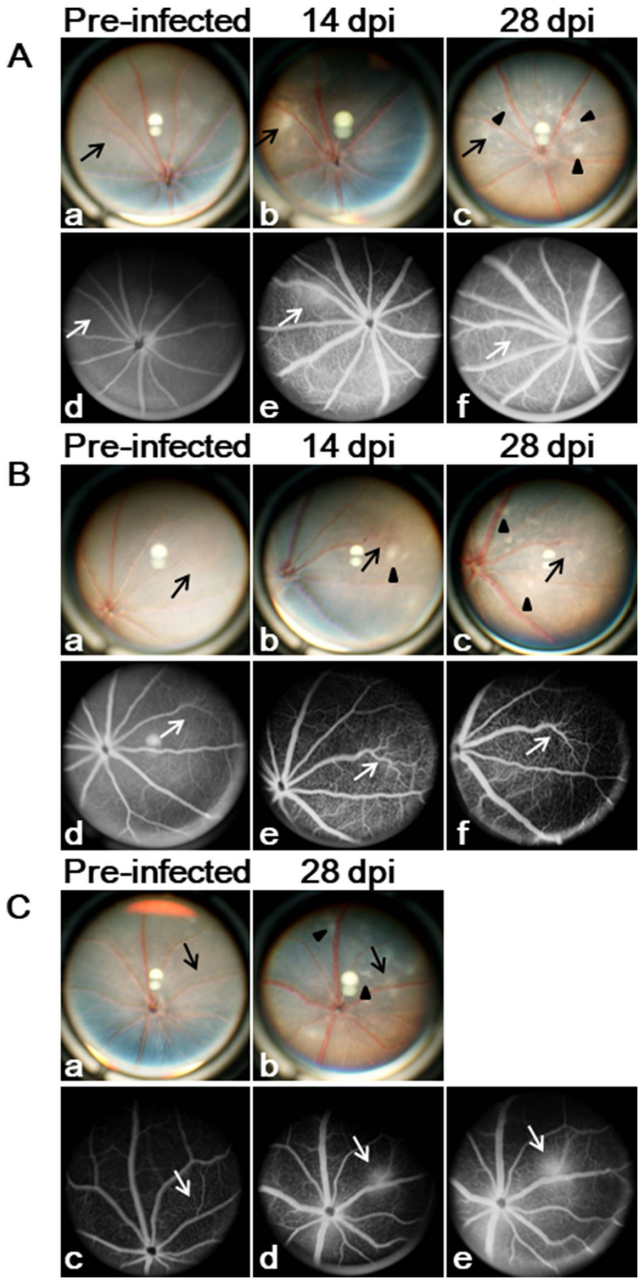

Figure 1. Representative ophthalmic observations. Panels **A, B**, and **C** show mouse nos. 13, 14, and 3, respectively. The upper parts of **A, B**, and **C** show fundus photographs, and the lower panels show fluorescein angiograms. Images **a** and **d** of panels **A** and **B**, and images **a** and **c** of panel **C** show mice before infection with *T. gondii*. Images **b** and **e** of panels **A** and **B** were taken at 14 dpi. Images **c** and **f** of panels **A** and **B**, and images **b**, **d**, and **e** of panel **C** were taken at 28 dpi. The *black arrows* in the fundus photographs and the *white arrows* in fluorescein angiogram images show different views of the same lesions. (**A**) The dense exudative lesion (*black arrow*) in image **b** shows active retinochoroiditis initially characterized by soft, small, multifocal, individual, slightly white-gray discolorations of the fundus. Image **e** shows the leakage of fluorescein dye (*white arrow*) from the area of this dense exudative lesion in image **b**. The exudative retinochoroiditis seen in image **b** became smaller and harder over time, as seen in image **c** (*black arrow*). The many hard white areas in image **c** (*black arrowheads*) indicate inactive lesions. Image **f** shows no further fluorescein leakage (*white arrow*). (**B**) The soft exudative lesions in image **b** indicate active lesions (*arrowhead*). The retinal vein was dilated and tortuous (*black arrow*). Image **e** shows a clear view of the dilatation and tortuosity of the retinal vein and fluorescein dye leakage (*white arrow*). Image **c** shows a less-dilated and less-tortuous retinal vein (*black arrow*) and many hard foci, indicating inactive lesions (*black arrowheads*). Image **f** shows a slightly less dilated and less tortuous vein compared with image **e**, indicating the inactive phase (*white arrow*). Because image **d** was taken without an excitation filter, the image was converted into grayscale. (**C**) The soft exudative lesions in image **b** are areas of active retinochoroiditis (*black arrow*). Hard white lesions indicate inactive lesions (*black arrowheads*). Image **d** shows a hyperfluorescent area indicating a disruption of the blood–retinal barrier at early phase (*white arrow*). Image **e**, taken 2 minutes, 32 seconds after image **d**, shows enlarged fluorescein leakage (*white arrow*).

Results

Ophthalmic Findings

Retinochoroidal lesions, such as focal exudative areas of retinochoroidal inflammation, were first observed at 14 dpi (Fig. 1). They were seen primarily at the posterior pole. Without treatment, these active lesions became harder over the next 14 days.

FA abnormalities were first observed at 14 dpi (Fig. 1). FA showed multifocal disruptions of the blood–retinal barrier, with late-phase fluorescein dye leakage into the sensory retina (Fig. 1Ae). Dilated and tortuous retinal veins were observed at 14 dpi, but by 28 dpi, these abnormalities decreased in severity (Fig. 1B). At 28 dpi, late hyperfluorescence was observed (Figs. 1Cd, 1Ce). FA showed no apparent abnormalities in the hard regions observed by fundus camera (Figs. 1Af, 1Bf). Most abnormalities identified with FA at 14 dpi resolved spontaneously by 28 dpi.

Histopathological and Immunohistochemical Findings

Uninfected mouse eyes and brains displayed normal morphology (Figs. 2A, 2B, and 2M). In the eye at 28 dpi, inflammatory cells were present in the anterior chamber (Fig. 2C) and vitreous (Figs. 2D and 2E). Retinal vasculitis and perivasculitis were evident around the larger retinal blood vessels (Figs. 2F and 2G). The retinas were edematous, folded, and displayed disorganized retinal architecture (Fig. 2F). Retinitis with inflammatory cell infiltration, pigment migration into the sensory retina, and disorganization of the retinal architecture were evident (Figs. 2H and 2I). *Toxoplasma* cysts were present with no visible host reaction (Figs. 2J–2L). In the brain at 28 dpi, inflammatory cells (Fig. 2N), vasculitis (Fig. 2O), and *Toxoplasma* cysts were present (Fig. 2P).

Immune Mediator Profiles

Figure 3A shows the measured Th1 cytokine levels. The postinfection IFN-γ, IL-12(p40), and IL-12(p70) levels were much higher in the AH and CSF compared with baselines levels; however, there were no differences between these levels, except for IL-12(p40), in the serum. The postinfection IL-12(p40) level in the serum was higher than that in uninfected mice but much lower than the postinfection IL-12(p40) levels in the AH or CSF. In uninfected mice, the IFN-γ and IL-12(p70) levels in the AH and CSF were much lower than those in the serum. In *T. gondii*–infected mice, the IL-12(p40) level in the CSF was much higher than that in the AH, but both levels were much higher than that in the serum. Regarding TNF-α, the postinfection level was much higher

Investigative Ophthalmology & Visual Science

Downloaded from abstracts.iovs.org on 04/26/2024

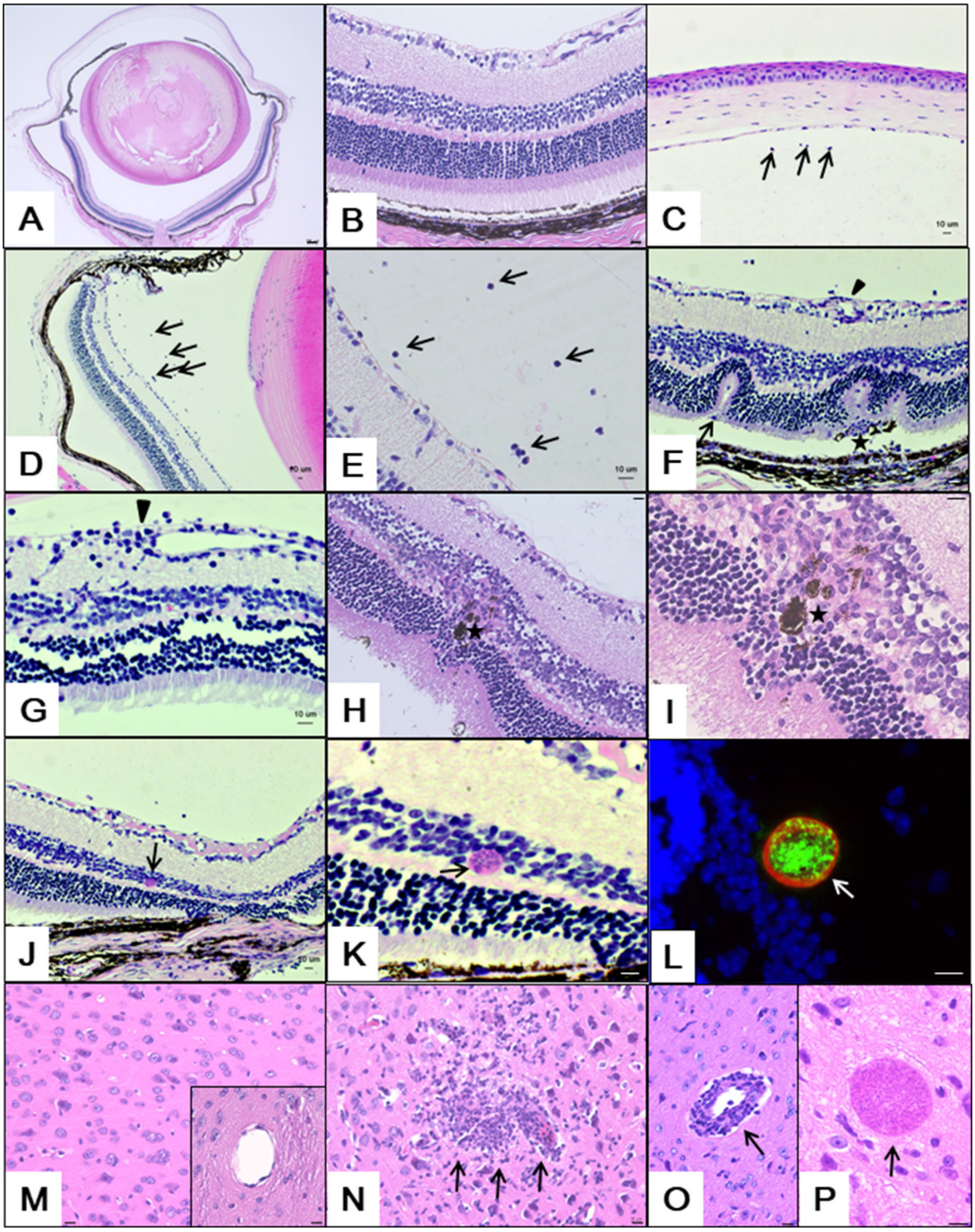

Figure 2. Histological and immunohistochemical findings at 0 and 28 dpi. Representative images of eye (**A–L**) and brain (**M–P**) sections. (**A**) Whole eye from an uninfected mouse. (**B**) Retina of an uninfected mouse eye. No infiltration of inflammatory cells was detected in the uninfected eyes. (**C**) Inflammatory cells were seen in the anterior chamber (*black arrows*). (**D**) Numerous inflammatory cells were present in the vitreous (*black arrows*). (**E**) Higher magnification image of the section shown in panel **D**. (**F**) Retinal vasculitis (*black arrowhead*), retinal fold (*black arrow*), and a subretinal granuloma (*black star*). The retina was edematous. Retinal degeneration, cellular layer disorganization, and subretinal granulomatous inflammation overlying the choroiditis foci were common, as were retinal pigment epithelium hyperplasia and hypertrophy. (**G**) Vasculitis was evident (*black arrowhead*). (**H**) An area of retinitis with accumulation of inflammatory cells and disorganization of the retinal architecture. Pigment migration into the retina (*black star*). (**I**) Higher magnification image of the section shown in **H**. Pigment migration into the sensory retina (*black star*). (**J**) *Toxoplasma* cyst present in the inner nuclear layer, with no host reaction (*black arrow*). (**K**) Higher-magnification image of the section shown in panel **J**; note the many tiny nuclei in the cyst (*black arrow*). (**L**) *Toxoplasma* cyst in the inner plexiform layer (*white arrow*) detected with immunohistochemistry using anti-*T. gondii* antibody (*green*) and *Dolichos*-binding lectin (*red*; cyst wall). (**M**) Brain from an uninfected mouse. The insert shows a blood vessel. (**N**) Infiltration of inflammatory cells in the brain (*black arrows*). (**O**) Vasculitis in the brain (*black arrow*). (**P**) *Toxoplasma* cyst (*black arrow*) filled with bradyzoites in the brain. **A–K** and **M–P**: Hematoxylin & eosin stain. *Scale bars*: 100 µm (**A**); 10 µm (**B–P**).

Investigative Ophthalmology & Visual Science

Downloaded from abstracts.iovs.org on 04/26/2024

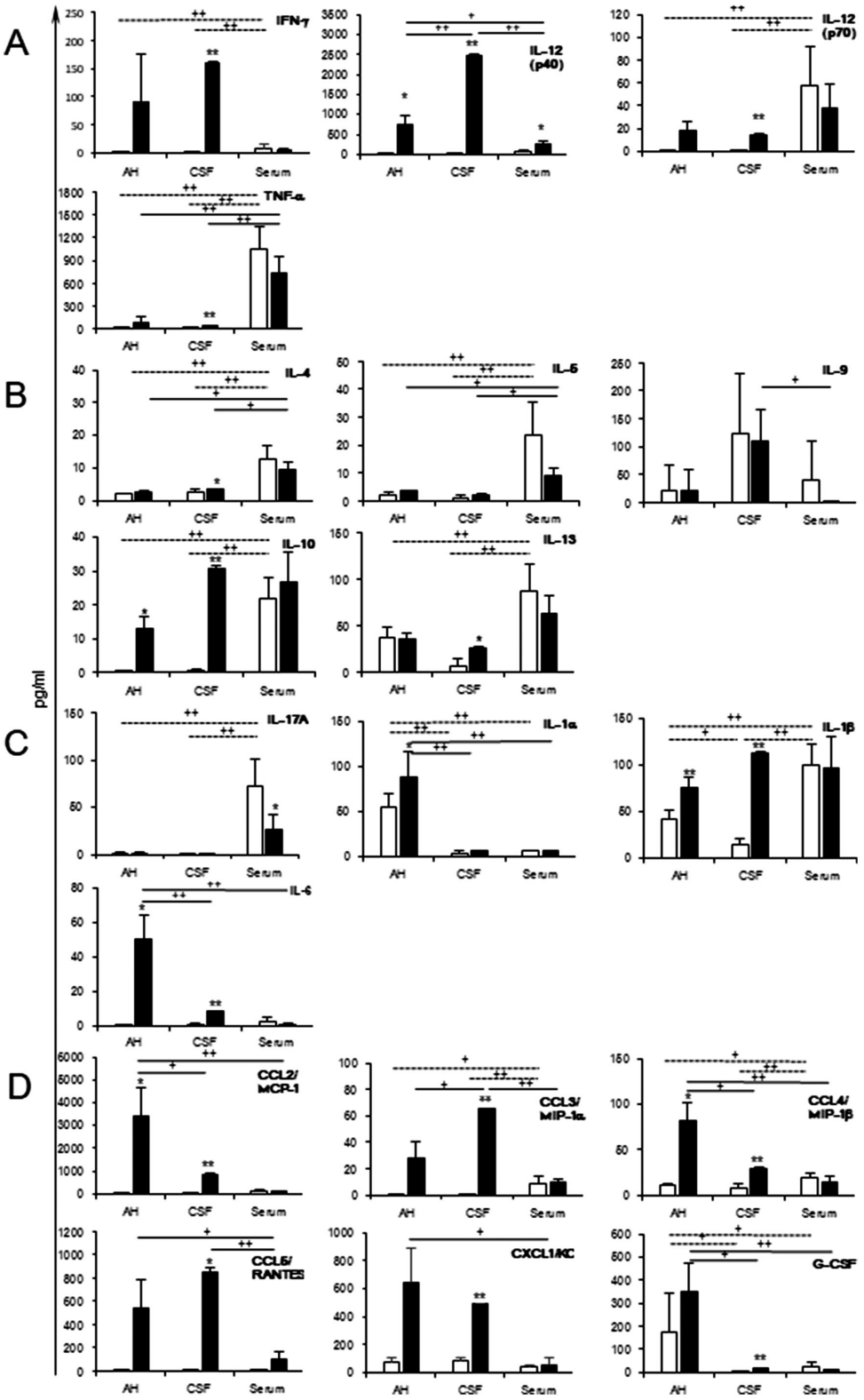

Figure 3. In vivo cytokine and chemokine production in the aqueous humor (AH), cerebral spinal fluid (CSF), and serum. Cytokine and chemokine levels were determined using a Bio-Plex Assay. Th1 (**A**), Th2 and Treg (**B**), and Th17 (**C**) cytokine profiles. (**D**) Chemokine and proinflammatory growth factor profiles. Values are the means ± SD of 3 independent experiments. Samples from 6 mice were pooled. *White bars*, uninfected mice; *black bars*, infected mice. * and ** show significant differences with $P < 0.05$ and $P < 0.01$, respectively, between uninfected and infected mice. + and ++ show significant differences with $P < 0.05$ and $P < 0.01$, respectively, between the AH and CSF, AH and serum, and CSF and serum of uninfected (*dotted line*) or infected (*solid line*) mice.

Investigative Ophthalmology & Visual Science

Downloaded from abstracts.iovs.org on 04/26/2024

than the baseline level in the CSF; for both uninfected and T. *gondii*–infected mice, the levels in the AH and CSF were significantly lower than those in sera.

Figure 3B shows the measured Th2 and Treg cytokine levels. Compared with baseline levels, the IL-10 level in the AH was higher, the IL-4, IL-10, and IL-13 levels in the CSF were higher, and the serum levels of these cytokines were not different after *T. gondii* infection. In uninfected mice, the IL-10 and IL-13 levels in the AH and CSF were much lower than those in the serum. The postinfection IL-9 level in the CSF was much higher than that in the serum. The IL-4 and IL-5 levels in the AH and CSF were significantly lower than those in sera for both uninfected and *T. gondii*–infected mice.

Figure 3C shows the measured Th17 cytokine levels. Compared with baseline levels, the postinfection IL-1α, IL-1β, and IL-6 levels in the AH were higher, the postinfection IL-1β and IL-6 levels in the CSF were higher, and the postinfection IL-17A level in the serum was lower. In uninfected mice, the IL-17A and IL-1β levels in the AH and CSF were much lower than those in sera, and the IL-1β level in the AH was much higher than that in the CSF. The postinfection IL-6 level in the AH was much higher than those in the CSF and serum. The IL-1α level in the AH was significantly higher than those in the CSF and serum of both uninfected and *T. gondii*–infected mice.

Figure 3D shows the measured chemokine and the proinflammatory growth factor levels. Compared with baseline levels, the postinfection levels of these chemokines in the AH and CSF were much higher, whereas those in the serum were not different. In uninfected mice, the CCL3/MIP-1α and CCL4/MIP-1β levels in the AH and CSF were much lower than those in the serum. In *T. gondii*–infected mice, the CCL2/MCP-1 and CCL4/MIP-1β levels in the AH were much higher than those in the CSF and serum, whereas the CCL3/MIP-1α level in the CSF was much higher than those in the AH and serum; additionally, the CCL5/RANTES levels in the AH and CSF and the CXCL1/KC level in the AH were much higher than those in sera. In both uninfected and *T. gondii*–infected mice, the G-CSF level in the AH was significantly higher than those in the CSF and serum. IL-2, IL-3, CCL11/eotaxin, and GM-CSF were undetectable or only faintly detectable in all examined samples (data not shown).

Discussion

In the present study, we report a murine model of primary acquired OT induced via the natural infection route, that is, peroral infection. Ophthalmologic and histopathologic findings revealed that our model at 28 dpi is at the subacute stage; additionally, *T. gondii* cysts with no host reaction were found in the retina and brain, indicating that this model at 28 dpi is also at the chronic stage.

There are some differences between our model and human OT. In an immunocompetent patient, resolution is reported to take six to eight weeks.[52] Over time, the lesion may become whiter, surrounded by an area of hyperpigmentation, that is, scar formation. Here, resolution began to occur at 28 dpi, which was 14 days after clinical manifestations appeared. Apparent scar formation with pigmentation could not be observed using the fundus camera and FA, probably because we conducted observations for only 28 days. However, both disorganization of the retinal pigment epithelium and pigment migration into the retina were found by histopathological examination even at 28 dpi, suggesting an enlargement of the forming scar with pigmentation.

The pathologic findings from our model were relatively mild compared with those of other murine models.[53–56] The reasons might be as follows: Many murine models of primary acquired OT are infected through unnatural routes, that is, intraperitoneal or intravitreal infection,[6,53–55,57] whereas our model uses the natural peroral infection route. Because mouse eyes are very small, the intravitreal infection itself causes remarkable mechanical damage.[54] Additionally, because the immune mechanisms between intraperitoneal infection and peroral infection are different,[58] the associated pathologic outcomes are different as well. Some congenital OT models were investigated pathologically,[56,59] and the peroral infection route was reported to cause fewer ocular pathologic changes compared with congenital infection.[59] Thus the route of infection might affect the pathologic outcome. Moreover, differences in parasite factors (such as the pathogenicity of *T. gondii* strains[48,60] and primary parasite load), host factors (such as mouse strain), or clinical stage factors (such as congenital or acquired, primary or recurrent, and acute or chronic) might influence the pathologic findings.

Table summarizes the findings of our present study and previous reports concerning immune mediator profiles in the AH, CSF, and serum during *T. gondii* infection. There are some contradictory results in Table, which might be related to the differences in human genetic predisposition and ages of the study participants,[60] in addition to the differences mentioned above in the pathologic findings.

There are five articles in which immune modulator profiles in *T. gondii*–infected mouse AH were analyzed.[41,45–48] Although the present work confirms previous reports regarding the postinfection levels of IL-6 and CXCL1/KC in the AH, other immune modulator profiles were partially different. These results indicate that IL-6 and CXCL1/KC have universal roles in the AH during OT, whereas other immune modulators might have specific roles depending on the particulars of the experimental design, such as infection route and parasite, host, and clinical factors.

Here, as in many previous reports, the IFN-γ, IL-12(p40), and IL-12(p70) levels in the AH and CSF increased after *T. gondii* infection.[22,24,25,36–38,40–43,45–48,61] Together with those reports, our findings indicate that, even in immunoprivileged organs, IFN-γ and IL-12 still play important roles in the subacute and chronic phases of *T. gondii* infection. However, Rochet et al.[48] reported that the levels of IFN-γ and IL-12 in the AH of mice are completely different according to the *T. gondii* strain. Additionally, the AH IFN-γ levels of Colombian patients did not increase, whereas those of French patients did,[42] indicating that a strain difference of *T. gondii* might affect IFN-γ levels. Furthermore, in TE patients with AIDS, there were no significant differences in the IFN-γ levels in the CFS and serum compared with control patients.[61] Here, the postinfection serum IFN-γ and IL-12(p40) levels were very low. The serum IFN-γ level has been reported to increase during the acute phase of toxoplasmosis but decrease during the chronic phase,[22,44,62–66] although elevated serum IFN-γ and IL-12 levels have also been reported in the chronic phase.[63,64]

TNF-α is a proinflammatory cytokine that plays a crucial protective role during *T. gondii* infection.[65] Here, the TNF-α levels in the AH and CSF were undetectable or very low compared with that in the serum for both uninfected

Investigative Ophthalmology & Visual Science

Downloaded from abstracts.iovs.org on 04/26/2024

Table. Cytokine and Chemokine Levels in the Aqueous Humor, Cerebral Spinal Fluid, and Serum

	Toxoplasmosis									Viral uveitis/ARN	IU
	Mouse (this study)			Mouse (other studies)			Human (other studies)			Human	Human
Group	AH	CSF	Serum	AH	CSF	Serum	AH	CSF	Serum	AH	AH
Type 1 cytokines											
IFN-γ	↑[‡]	↑	N.S.	↑41, 45[§], 46, 47, 47[§], 48 N.S. 48	↑22, 24, 25	↑ 23, 24, 46, 63, 64 ↑ then ↓ 22, 62, 66	↑ 36, 37, 38, 40, 41, 42, 43, 43[§] N.S. 42	N.S. 61[#]	↑ then ↓ 44 N.S. 44, 61[#], 78	↑ 33, 36, 38, 40 N.S. 31, 35[‡]	↑ 31, 38 N.S. 34
IL-12(p40)	↑	↑	↑	↑45[§], 48 N.S. 46[*], 48		↑25, 64[*] N.D. 46[*]	↑36[*]	↑61[‡ * #]	↑ 61[* #]	N.S. 36[*]	↓ 34[*]
IL-12(p70)	↑[‡]	↑	N.S.	↑ 48 N.S. 48		↑67	↑42 N.S. 37, 38, 43, 43[§]			↑ 38 ↓ 31 N.S. 35	↓ 31 N.S. 38
TNF-α	N.S.	↑	N.S.	↑41, 47, 47[§], 48 N.S. 46, 48	↑22[**], 23[**], 25[**]	↑22[**], 23[**], 63, 67 [**]↑ then ↓ 62, 66 N.S. 46	↑36, 37, 42, 43, 43[§] N.S. 38, 41, 42		↑ then ↓ 44 N.S. 44, 78	↑36 N.S. 33, 35, 38	↓34 N.S. 38
IL-2	N.D.	N.D.	N.D.	↑ 41, 47, 48 ↑ then ↓ 47[§] N.S. 48			↑ 36, 40‖, 41, 42, 43, 43[§] N.S. 38, 42		↑ then ↓ 44 N.S. 44, 78	↑ 38 ↓ 31 N.S. 33, 35, 36, 40	↑ 38 ↓ 31, 34
Type 2 cytokines											
IL-3	N.D.	N.D.	N.S.								
IL-4	N.S.	↑	N.S.	↑ 48 N.S. 48 N.D. 46		↑63 N.D. 46	↑36, 37, 42, 43, 43[§] N.S. 38, 40		↑ then ↓ 44 N.S. 44	↑ 36, 38 N.S. 33, 35, 40	↑ 38
IL-5	N.S.	N.S.	N.S.	↑ 48			↑36, 38, 42, 43, 43[§] N.S. 37, 42			↑36, 38 N.S. 33, 35	↑ 38
IL-9	N.S.	N.S.	N.S.				↑ 43, 43[§] N.S. 37, 38, 42			N. S. 38	↑ 34 N.S. 38
IL-10	↑	↑	N.S.	↑41, 47, 47[§], 48 ↓46 N.S. 45[§], 48	↑25	↑64 ↓46, 63	↑ 36, 40, 41, 42 N.S. 37, 38, 42, 43, 43[§]		↑ then ↓ 44 N.S. 44, 78	↑ 31, 33, 35, 36, 38, 40	N.S. 31, 34, 38
IL-13	N.S.	↑	N.S.	↑41, 47, 47[§], 48 minimal upregulation 45[§] N.S. 48			↑36, 37, 41, 42, 43 N.S. 38, 42, 43[§]			↑ 36, 38 ↓ 31 N.S. 35	↑ 38 ↓ 31

Downloaded from abstracts.iovs.org on 04/26/2024

Table. Continued

	Toxoplasmosis									Viral uveitis/ARN	IU
	Mouse (this study)			Mouse (other studies)			Human (other studies)			Human	Human
Group	AH	CSF	Serum	AH	CSF	Serum	AH	CSF	Serum	AH	AH
Th17 cytokines											
IL-17A	N.S.	N.S.	↓	↑ 41[***], 45[§], 47, 48 N.S. 47[§], 48			↑36[***], 38, 41[***], 42, 43[***], 43[***§] N.S. 37[***], 42			N. S. 35, 36 [***], 38	N.S. 38
IL-1α	↑	N.S.	N.S.	↑ 48 N.S. 48		↑63[†]					
IL-1β	↑	↑	N.S.	↑ 48 N.S. 48			↑36, 42, 43, 43[§] N.S. 37, 38, 42		↑ then ↓ 44 N.S. 44, 78	↑36, 38 N.S. 35	N.S. 38
IL-6	↑	↑	N.S.	↑ 41, 45[§], 46, 47, 47[§], 48	↑22, 25	↑ 46, 63, 67 ↑ then ↓ 22, 66	↑36, 37, 38, 39, 40, 41, 42, 43, 43[§]	↑21[#]	↑ then ↓ 44 N.S. 39, 44, 78	↑ 35, 36, 38, 40 N.S. 31	↑ 31, 34, 38
Chemokines and growth factors											
CCL2/MCP-1	↑	↑	N.S.	↑41, 45[§], 47, 48 N.S. 47[§]	↑ 25	↑ 67 ↑ then ↓ 62	↑36, 37, 38, 41, 42, 43, 43[§] N.S. 42	N.S. 26[#]	↑ then ↓ 44 ↓78 N.S. 44, 81	↑31, 35, 36, 38	↑ 31, 34, 38
CCL3/MIP-1α	↑[‡]	↑	N.S.	↑ 48 N.S. 48			↑37, 38, 43, 43[§] N.S. 42	N.S. 26[#]	N.S. 44	↑38 N.S. 35	↑ 38
CCL4/MIP-1β	↑	↑	N.S.	↑45[§], 48 N.S. 48			↑36, 38, 42, 43 N.S. 37, 42, 43[§]			↑ 36, 38	↑ 38
CCL5/RANTES	↑[‡]	↑	N.S.	↑45[§], 48 N.S. 48			↑37, 38, 42, 43, 43[§] N.S. 42	N.S. 26[#]	↑81	↑38 N.S. 35	N.S. 38
CCL11/eotaxin	N.D.	N.D.	N.D.	↑ 48 N.S. 48			↑38, 43, 43[§] N.S. 37, 42		↑ then ↓ 44 ↓ 44 N.S. 44	↑ 35, 38	↑ 38
CXCL1/KC	↑[‡]	↑	N.S.	↑45[§], 48							
G-CSF	N.S.	↑	N.S.	↑45[§], 48			↑36, 37, 38, 42, 43, 43[§] N.S. 42		N.S. 78	↑ 36, 38	↑ 38
GM-CSF	N.D.	N.D.	N.D.	↑ 48 N.S. 48			↑42, 43 ↓ 36 N.S. 37, 38, 42, 43[§]		↑ then ↓ 44 N.S. 44	↑ 36 N.S. 38	N.S. 38

Numbers in the table indicate the reference numbers. Statistical analysis between the uninfected mice and infected mice was not performed in the study described in reference 47. The study described in reference 45 analyzed both resistant and susceptible mice, but this table shows only the data from the susceptible mice. IU, idiopathic uveitis; N.D., significant levels were not detected; N.S., not significant; ↑, increased; ↓, decreased.

* IL-12.
** TNF.
***IL-17.
† IL-1.
‡ Increase that failed to reach statistical significance.
§ Reactivation model (data from only susceptible mice)/recurrent.
‖ Only 1 patient out of 27 detected.
AIDS/HIV-infected patients.

Downloaded from abstracts.iovs.org on 04/26/2024

and *T. gondii*–infected mice, although the postinfection CSF TNF-α level was significantly increased. Many reports have described that the serum TNF(-α) level increases during the acute phase of *T. gondii* infection[22,23,44,62,63,66,67] and decreases thereafter.[44,62,66] However, increased serum TNF-α levels in the chronic phase have also been reported.[63] Here, the T-cell growth factor IL-2[68] was undetectable in all samples.

IL-10 plays a key role in immune system regulation and prevents excessive tissue damage during *T. gondii* infection.[17,69] Here, the postinfection IL-10 levels were significantly higher in the AH and CSF, in agreement with previous reports,[25,36,40–42,47,48] but the serum IL-10 levels were not significantly different. The levels of other Th2- and Treg-type cytokines in the AH and serum did not change following *T. gondii* infection, which is not unexpected given that *T. gondii* infection induces a Th1-polarized immune response. However, some prior studies reported different findings.[36–38,41–45,47,48,63] In patients infected with type I/III *T. gondii* strains, a Th2 response was associated with more severe clinical characteristics.[37] IL-4 and IL-13 levels have been positively correlated with the number and size of active lesions, and IL-5 has been described as a predictor of OT recurrence.[37]

After *T. gondii* infection, the proinflammatory cytokine IL-17A recruits neutrophils to the site of inflammation.[41,70] Here, minimal amounts of IL-17A were detected in the AH and CSF of both uninfected and *T. gondii*–infected mice. In murine studies of very acute or subacute *T. gondii* infection, the reported expression levels of IL-17A in the retina or IL-17 levels in the AH were variable.[20,41,45,47,48] In human acute OT, some studies found a significant elevation of the AH IL-17(A) level compared with that in control subjects,[36,38,41–43] whereas other studies did not find a significant difference between these groups.[37,42] Thus *T. gondii* strain differences might cause different results regarding the IL-17 levels in the AH, as they do for IFN-γ levels.[37,42,48] Notably, the serum IL-17A level was significantly lower in *T. gondii*–infected mice compared with uninfected mice in the present study. We previously reported significant leukocytopenia, especially lymphocytopenia, after *T. gondii* infection.[71] Thus the postinfection number of IL-17A-producing Th17 cells might be decreased in the peripheral blood, or these cells might be accumulated at the site of inflammation, accounting for the decreased serum IL-17A level of *T. gondii*–infected mice in this model.

IL-1 modulates the host immune defenses against *T. gondii* infection.[63] Here, the postinfection IL-1α level in the AH and IL-1β levels in the AH and CSF, but not in the serum, increased significantly over baseline levels. In both mouse and human OT, the AH IL-1β level was contradictory.[36–38,42,43,48] Serum IL-1β levels were reported to rise significantly during chronic *T. gondii* infection in camels.[72]

IL-6 is a multifunctional cytokine, produced by Th2 cells and several other cells, found in high concentrations in intraocular fluids during uveitis.[31,34–36,38,40,73–77] Here, the postinfection IL-6 levels in the AH and CSF, but not in the serum, were significantly higher than baseline levels, consistent with previous reports.[21,22,25,36–43,45–48] The AH IL-6 levels were reported to be higher in patients with active OT compared with those whose disease was nonactive.[40] In serum, IL-6 levels have been reported to increase during the acute-phase[22,46,63,66,67] and decrease thereafter[22,66] or to not differ from baseline levels or not differ between phases.[39,44,78] These data indicate that IL-6 in the AH plays a crucial role in the immunopathogenesis of active OT and that IL-6 in the AH but not in the serum might be an indicator of disease status.

Chemokines plays a pivotal role in the recruitment of inflammatory cells during *T. gondii* infection.[18,79,80] We previously reported that the expression of chemokines was upregulated in the retina and brain of *T. gondii*–infected mice.[20] The chemokine/cytokine cross-talk may change during the stages of OT.[44,81] Our study demonstrated that the postinfection levels of chemokines, such as CCL2/MCP-1, CCL3/MIP-1α, CCL4/MIP-1β, CCL5/RANTES, and CXCL1/KC, in the AH and CSF, but not in the serum, were significantly increased over baseline levels, in agreement with other work.[25,36–38,41–45,47,48] In contrast with our present study, the serum CCL2/MCP-1 level was reported to increase during the acute phase of *Toxoplasma* infection[44,62,67] and to decrease during the chronic phase.[44,62] However, some reports show opposing findings: the serum level of CCL2/MCP-1 was significantly lower in patients with active OT than in healthy subjects, which suggests that a reduced serum level of CCL2/MCP-1 is associated with active OT and could be used as a marker of disease activity.[78] In HIV-infected patients, the levels of these chemokines were not increased in the CSF.[26]

G-CSF contributes to the robust proinflammatory response induced by *T. gondii* infection.[82] Here, the postinfection G-CSF levels in the AH and CSF tended to be higher. The AH G-CSF levels increased in a toxoplasmosis reactivation mouse model[45] and in human OT.[36–38,42,43] CCL11/eotaxin simulates eosinophil migration.[83] GM-CSF is a major inflammation mediator that also functions in maintaining homeostasis,[84] and it seems to be specifically produced during viral uveitis.[36] Neither CCL11/eotaxin nor GM-CSF was detected in any samples in this study. CCL11/eotaxin was reported to be selectively induced in the serum of patients who developed OT, although the CCL11/eotaxin level was lower in toxoplasmosis patients than in healthy donors.[44] Serum GM-CSF levels were higher in the acute stage of toxoplasmosis than in the chronic stage.[44]

The postinfection IL-1α, IL-6, CCL2/MCP-1, CCL4/MIP-1β, and G-CSF levels in the AH were much higher than those in the CSF and serum, indicating that these molecules might play an important role in the eye of this model. However, the postinfection levels of many immune mediators, except TNF-α, IL-4, and IL-5, in the AH and CSF were significantly higher than those in the serum, which suggests that, in this model, these molecules might play vital roles specifically in immune-privileged organs, that is, the eyes and brain, rather than in systemic organs during toxoplasmosis. Furthermore, our study demonstrated that the postinfection profiles of these molecules, except IL-1α, IL-4, and IL-13, in the AH and CSF were very similar. Therefore, although OT immunopathogenesis might be very similar to TE immunopathogenesis, some OT-specific immune mechanisms may exist. This possibility needs further investigation because there are only a few reports concerning the levels of these immune mediators in the CSF, and there are no reports simultaneously investigating the levels of these molecules in both the AH and CSF (Table).

Table also shows AH immune modulator profiles of virus uveitis/acute retinal necrosis and idiopathic uveitis. Elevated concentrations of these molecules in the AH have been reported for different uveitis types, and diverse profiles can characterize specific diseases.[31,32,34,36,38,85] Investigating these profiles will extend our understanding of the

Investigative Ophthalmology & Visual Science

Downloaded from abstracts.iovs.org on 04/26/2024

immunopathogenic mechanisms of uveitis.[32] There are only few reports directly comparing these molecules in the AH between OT and other uveitis, and their findings are contradictory.[35,36,38,40] Consequently, the profiles of these molecules will be useful diagnostic and prognostic tools for clinicians in the future,[86] when more precise investigations reveal the association between these molecules and each uveitis.

This study analyzed immune mediator levels only at the subacute to chronic phase. Therefore a further analysis of these molecules at the acute phase is needed to understand human OT more in detail so that AH assessment can be used for early diagnosis. Because differences among the ophthalmic findings in congenital/recurrent OT and postnatally primary acquired OT, and in OT caused by different *T. gondii* strains are a subject of discussion,[6] to improve the reliability of applying animal OT models to understanding human OT, the generation of a congenital/recurrence model is required in the future, as well as models using different strains of *T. gondii*. Additionally, the investigation of antibody titers in the AH and serum using an animal model of OT is also needed, because some patients do not show positive serum IgM,[87] indicative of chronic infection, making it difficult to diagnose human OT.

In summary, this murine primary acquired OT model allows detailed ophthalmological and immunological evaluations and provides new insight into human OT immunopathogenesis. Additionally, investigating AH immune modulators may be useful for the differential diagnosis of uveitis, and these inflammatory molecules may provide targets for therapeutic intervention.

Acknowledgments

The authors thank Nasreen A. Syed, Ophthalmology and Pathology Director, F.C. Blodi Eye Pathology Laboratory, University of Iowa, for her helpful discussion of our histological findings. The authors thank Yoshihito Ozawa and Yuki Shiko, Biostatistics Section, Clinical Research Center, Chiba University Hospital, Japan, and Yohei Kawasaki, Biostatistics Section, Clinical Research Center, Chiba University Hospital, Japan and Clinical Research Data Center, Chiba University Hospital, Japan for their helpful discussion about the statistical analysis of the data. The authors also thank Katie Oakley, PhD, from Edanz Group (https://en-author-services.edanz.com/ac) for editing a draft of this manuscript.

Supported by Grant-in-Aid 26460505 from the Japanese Science Promotion Society.

Disclosure: **K. Li,** None; **X. Feng,** None; **K. Hikosaka,** None; **K. Norose,** None

References

1. Holland GN, O'Connor GR, Belfort R, Jr., Remington JS. Toxoplasmosis. In: Pepose JS, Holland GN, Wilhelmus KR, eds. *Ocular Infection & Immunity*. St. Louis: Mosby; 1996:1183–1223.
2. Montoya JG, Liesenfeld O. Toxoplasmosis. *Lancet*. 2004;363:1965–1976.
3. Perkins ES. Ocular toxoplasmosis. *Br J Ophthalmol*. 1973;57:1–17.
4. Gilbert RE, Stanford MR. Is ocular toxoplasmosis caused by prenatal or postnatal infection? *Br J Ophthalmol*. 2000;84:224–226.
5. Kijlstra A, Petersen E. Epidemiology, pathophysiology, and the future of ocular toxoplasmosis. *Ocul Immunol Inflamm*. 2014;22:138–147.
6. Maenz M, Schlüter D, Liesenfeld O, Schares G, Gross U, Pleyer U. Ocular toxoplasmosis past, present and new aspects of an old disease. *Prog Retin Eye Res*. 2014;39:77–106.
7. Pleyer U, Schlüter D, Mänz M. Ocular toxoplasmosis: recent aspects of pathophysiology and clinical implications. *Ophthalmic Res*. 2014;52:116–123.
8. Bosch-Driessen LE, Berendschot TT, Ongkosuwito JV, Rothova A. Ocular toxoplasmosis: clinical features and prognosis of 154 patients. *Ophthalmology*. 2002;109:869–878.
9. Holland GN. Reconsidering the pathogenesis of ocular toxoplasmosis. *Am J Ophthalmol*. 1999;128:502–505.
10. Holland GN. Ocular toxoplasmosis: a global reassessment. Part I: epidemiology and course of disease. *Am J Ophthalmol*. 2003;136:973–988.
11. Masur H, Jones TC, Lempert JA, Cherubini TD. Outbreak of toxoplasmosis in a family and documentation of acquired retinochoroiditis. *Am J Med*. 1978;64:396–402.
12. Choi WY, Nam HW, Kwak NH, Huh W, Kim YR, Kang MW, Cho SY, Dubey JP. Foodborne outbreaks of human toxoplasmosis. *J Infect Dis*. 1997;175:1280–1282.
13. Ross RD, Stec LA, Werner JC, Blumenkranz MS, Glazer L, Williams GA. Presumed acquired ocular toxoplasmosis in deer hunters. *Retina*. 2001;21:226–229.
14. Palanisamy M, Madhavan B, Balasundaram MB, Andavar R, Venkatapathy N. Outbreak of ocular toxoplasmosis in Coimbatore, India. *Indian J Ophthalmol*. 2006;54:129–131.
15. Balasundaram MB, Andavar R, Palaniswamy M, Venkatapathy N. Outbreak of acquired ocular toxoplasmosis involving 248 patients. *Arch Ophthalmol*. 2010;128:28–32. Erratum in: *Arch Ophthalmol*. 2010;128:508.
16. Suzuki Y, Orellana MA, Schreiber RD, Remington JS. Interferon-γ: the major mediator of resistance against *Toxoplasma gondii*. *Science*. 1988;240:516–518.
17. Dupont CD, Christian DA, Hunter CA. Immune response and immunopathology during toxoplasmosis. *Semin Immunopathol*. 2012;34:793–813.
18. Denkers EY, Butcher BA, Del Rio L, Bennouna S. Neutrophils, dendritic cells and *Toxoplasma*. *Int J Parasitol*. 2004;34:411–421.
19. Norose K, Kikumura A, Luster AD, Hunter CA, Harris TH. CXCL10 is required to maintain T-cell populations and to control parasite replication during chronic ocular toxoplasmosis. *Invest Ophthalmol Vis Sci*. 2011;52:389–398.
20. Kikumura A, Ishikawa T, Norose K. Kinetic analysis of cytokines, chemokines, chemokine receptors and adhesion molecules in murine ocular toxoplasmosis. *Br J Ophthalmol*. 2012;96:1259–1267.
21. Torre D, Zeroli C, Ferraro G, et al. Cerebrospinal fluid levels of IL-6 in patients with acute infections of the central nervous system. *Scand J Infect Dis*. 1992;24:787–791.
22. Schlüter D, Deckert-Schlüter M, Schwendemann G, Brunner H, Hof H. Expression of major histocompatibility complex class II antigens and levels of interferon-γ, tumour necrosis factor, and interleukin-6 in cerebrospinal fluid and serum in *Toxoplasma gondii*-infected SCID and immunocompetent C.B-17 mice. *Immunology*. 1993;78:430–435.
23. Deckert-Schlüter M, Schlüter D, Schmidt D, Schwendemann G, Wiestler OD, Hof H. *Toxoplasma* encephalitis in congenic B10 and BALB mice: impact of genetic factors on the immune response. *Infect Immun*. 1994;62:221–228.
24. Schlüter D, Bertsch D, Frei K, et al. Interferon-γ antagonizes transforming growth factor-β_2-mediated immunosuppression in murine *Toxoplasma* encephalitis. *J Neuroimmunol*. 1998;81:38–48.

Investigative Ophthalmology & Visual Science

Downloaded from abstracts.iovs.org on 04/26/2024

25. Jin D, Takamoto M, Hu T, Taki S, Sugane K. STAT6 signalling is important in CD8$^+$ T-cell activation and defence against *Toxoplasma gondii* infection in the brain. *Immunology.* 2009;127:187–195.
26. Christo PP, Vilela Mde C, Bretas TL, et al. Cerebrospinal fluid levels of chemokines in HIV infected patients with and without opportunistic infection of the central nervous system. *J Neurol Sci.* 2009;287:79–83.
27. Harris TH, Banigan EJ, Christian DA, et al. Generalized Lévy walks and the role of chemokines in migration of effector CD8$^+$ T cells. *Nature*. 2012;486:545–548.
28. Rothova A, de Boer JH, Ten Dam-van Loon NH, et al. Usefulness of aqueous humor analysis for the diagnosis of posterior uveitis. *Ophthalmology.* 2008;115:306–311.
29. Alfonso Y, Fraga J, Fonseca C, et al. Molecular diagnosis of *Toxoplasma gondii* infection in cerebrospinal fluid from AIDS patients. *Cerebrospinal Fluid Res*. 2009;6:2.
30. Mikita K, Maeda T, Ono T, Miyahira Y, Asai T, Kawana A. The utility of cerebrospinal fluid for the molecular diagnosis of toxoplasmic encephalitis. *Microbiol Infect Dis.* 2013;75:155–159.
31. Curnow SJ, Falciani F, Durrani OM, et al. Multiplex bead immunoassay analysis of aqueous humor reveals distinct cytokine profiles in uveitis. *Invest Ophthalmol Vis Sci.* 2005;46:4251–4259.
32. Ooi KG, Galatowicz G, Calder VL, Lightman SL. Cytokines and chemokines in uveitis: is there a correlation with clinical phenotype? *Clin Med Res.* 2006;4:294–309.
33. Takase H, Futagami Y, Yoshida T, et al. Cytokine profile in aqueous humor and sera of patients with infectious or noninfectious uveitis. *Invest Ophthalmol Vis Sci.* 2006;47:1557–1561.
34. Ang M, Cheung G, Vania M, et al. Aqueous cytokine and chemokine analysis in uveitis associated with tuberculosis. *Mol Vis.* 2012;18:565–573.
35. de Visser L, H de Boer J, T Rijkers G, et al. Cytokines and chemokines involved in acute retinal necrosis. *Invest Ophthalmol Vis Sci.* 2017;58:2139–2151.
36. Lahmar I, Abou-Bacar A, Abdelrahman T, et al. Cytokine profiles in toxoplasmic and viral uveitis. *J Infect Dis.* 2009;199:1239–1249.
37. de-la-Torre A, Pfaff AW, Grigg ME, Villard O, Candolfi E, Gomez-Marin JE. Ocular cytokinome is linked to clinical characteristics in ocular toxoplasmosis. *Cytokine.* 2014;68:23–31.
38. Sauer A, Villard O, Creuzot-Garcher C, et al. Intraocular levels of interleukin 17A (IL-17A) and IL-10 as respective determinant markers of toxoplasmosis and viral uveitis. *Clin Vaccine Immunol.* 2015;22:72–78.
39. Murray PI, Hoekzema R, van Haren MA, de Hon FD, Kijlstra A. Aqueous humor interleukin-6 levels in uveitis. *Invest Ophthalmol Vis Sci.* 1990;31:917–920.
40. Ongkosuwito JV, Feron EJ, van Doornik CE, et al. Analysis of immunoregulatory cytokines in ocular fluid samples from patients with uveitis. *Invest Ophthalmol Vis Sci.* 1998;39:2659–2665.
41. Sauer A, Pfaff AW, Villard O, et al. Interleukin 17A as an effective target for anti-inflammatory and antiparasitic treatment of toxoplasmic uveitis. *J Infect Dis.* 2012;206:1319–1329.
42. de-la-Torre A, Sauer A, Pfaff AW, et al. Severe South American ocular toxoplasmosis is associated with decreased Ifn-γ/Il-17a and increased Il-6/Il-13 intraocular levels. *PLoS Negl Trop Dis.* 2013;7:e2541.
43. Thieme C, Schlickeiser S, Metzner S, Dames C, Pleyer U. Immune mediator profile in aqueous humor differs in patients with primary acquired ocular toxoplasmosis and recurrent acute ocular toxoplasmosis. *Mediators Inflamm*. 2019;2019:9356728.
44. Marino AP, Dos Santos LI, Henriques PM, et al. Circulating inflammatory mediators as biomarkers of ocular toxoplasmosis in acute and in chronic infection. *J Leukoc Biol.* 2020;108:1253–1264.
45. Rochet E, Brunet J, Sabou M, et al. Interleukin-6-driven inflammatory response induces retinal pathology in a model of ocular toxoplasmosis reactivation. *Infect Immun.* 2015;83:2109–2117.
46. Calabrese KS, Tedesco RC, Zaverucha do Valle T, Barbosa HS. Serum and aqueous humour cytokine response and histopathological alterations during ocular *Toxoplasma gondii* infection in C57BL/6 mice. *Micron.* 2008;39:1335–1341.
47. Sauer A, Rochet E, Lahmar I, et al. The local immune response to intraocular *Toxoplasma* re-challenge: less pathology and better parasite control through Treg/Th1/Th2 induction. *Int J Parasitol.* 2013;43:721–728.
48. Rochet E, Argy N, Greigert V, Brunet J, Sabou M, Marcellin L, de-la-Torre A, Sauer A, Candolfi E, Pfaff AW. Type I ROP16 regulates retinal inflammatory responses during ocular toxoplasmosis. *PLoS One*. 2019;14:e0214310.
49. Norose K, Aosai F, Mizota A, Yamamoto S, Mun HS, Yano A. Deterioration of visual function as examined by electroretinograms in *Toxoplasma gondii*-infected IFN-γ-knockout mice. *Invest Ophthalmol Vis Sci.* 2005;46:317–321.
50. Norose K, Mun HS, Aosai F, et al. IFN-γ-regulated *Toxoplasma gondii* distribution and load in the murine eye. *Invest Ophthalmol Vis Sci*. 2003;44:4375–4381.
51. Liu L, Duff K. A technique for serial collection of cerebrospinal fluid from the cisterna magna in mouse. *J Vis Exp*. 2008;(21):960.
52. Rothova A. Ocular involvement in toxoplasmosis. *Br J Ophthalmol*. 1993;77:371–377. Erratum in: *Br J Ophthalmol*. 1993;77:683.
53. Hu MS, Schwartzman JD, Yeaman GR, et al. Fas-FasL interaction involved in pathogenesis of ocular toxoplasmosis in mice. *Infect Immun*. 1999;67:928–935.
54. Tedesco RC, Smith RL, Corte-Real S, Calabrese KS. Ocular toxoplasmosis in mice: comparison of two routes of infection. *Parasitology*. 2005;131:303–307.
55. Rocha AC, Calabrese Kda S, Tedesco RC, et al. Morphometric changes in C57BL/6 mice retina infected by *Toxoplasma gondii* ME 49 strain. *Exp Parasitol*. 2014;136:1–4.
56. Lahmar I, Guinard M, Sauer A, Marcellin L, Abdelrahman T, Roux M, Mousli M, Moussa A, Babba H, Pfaff AW, Candolfi E. Murine neonatal infection provides an efficient model for congenital ocular toxoplasmosis. *Exp Parasitol*. 2010;124:190–196.
57. Roberts F, Kuo A, Jones L, McLeod R, Roberts CW. Ocular toxoplasmosis: Clinical features, pathology, pathogenesis, animal models, and immune responses. Eds. Ajioka JW, Soldati D. *Toxoplasma molecular and cellular biology*. Norfolk, UK: Horizon Bioscience; 2007:59–91.
58. Johnson AM. Strain-dependent, route of challenge-dependent, murine susceptibility to toxoplasmosis. *Z Parasitenkd*. 1984;70:303–309.
59. Ashour DS, Saad AE, El Bakary RH, El Barody MA. Can the route of *Toxoplasma gondii* infection affect the ophthalmic outcomes? *Pathog Dis*. 2018;76.
60. Fernández C, Jaimes J, Ortiz MC, Ramírez JD. Host and *Toxoplasma gondii* genetic and non-genetic factors influencing the development of ocular toxoplasmosis: a systematic review. *Infect Genet Evol*. 2016;44:199–209.
61. Torre D, Zeroli C, Ferrario G, et al. Levels of nitric oxide, gamma interferon and interleukin-12 in AIDS patients with toxoplasmic encephalitis. *Infection*. 1999;27:218–220.
62. Aviles H, Stiles J, O'Donnell P, et al. Kinetics of systemic cytokine and brain chemokine gene expression in murine *Toxoplasma* infection. *J Parasitol*. 2008;94:1282–1288.

Investigative Ophthalmology & Visual Science

Downloaded from abstracts.iovs.org on 04/26/2024

63. Bottari NB, Baldissera MD, Tonin AA, et al. Effects of sulfamethoxazole-trimethoprim associated to resveratrol on its free form and complexed with 2-hydroxypropyl-β-cyclodextrin on cytokines levels of mice infected by*Toxoplasma gondii*. *Microb Pathog*. 2015;87:40–44.
64. Oliveira CB, Meurer YS, Medeiros TL, et al. Anti-*Toxoplasma* activity of estragole and thymol in murine models of congenital and noncongenital toxoplasmosis. *J Parasitol*. 2016;102:369–376.
65. Gazzinelli RT, Brézin A, Li Q, Nussenblatt RB, Chan CC. *Toxoplasma gondii*: acquired ocular toxoplasmosis in the murine model, protective role of TNF-α and IFN-γ. *Exp Parasitol*. 1994;78:217–229.
66. Dias RR, Carvalho EC, Leite CC, et al. *Toxoplasma gondii* oral infection induces intestinal inflammation and retinochoroiditis in mice genetically selected for immune oral tolerance resistance. *PLoS ONE*. 2014;9:e113374.
67. Heimesaat MM, Fischer A, Kuhl AA, Gobel UB, Gozes I, Bereswill S. Anti-inflammatory properties of NAP in acute *Toxoplasma gondii*-induced ileitis in mice. *Eur J Microbiol Immunol*. 2015;5:210–220.
68. Abbas AK, Trotta E, R Simeonov D, Marson A, Bluestone JA. Revisiting IL-2: biology and therapeutic prospects. *Sci Immunol*. 2018;3: eaat1482.
69. Lu F, Huang S, Kasper LH. Interleukin-10 and pathogenesis of murine ocular toxoplasmosis. *Infect Immun*. 2003;71:7159–7163.
70. Kelly MN, Kolls JK, Happel K, et al. Interleukin-17/interleukin-17 receptor-mediated signaling is important for generation of an optimal polymorphonuclear response against *Toxoplasma gondii* infection. *Infect Immun*. 2005;73:617–621.
71. Norose K, Naoi K, Fang H, Yano A. *In vivo* study of toxoplasmic parasitemia using interferon-γ-deficient mice: absolute cell number of leukocytes, parasite load and cell susceptibility. *Parasitol Int*. 2008;57:447–453.
72. Azma F, Razavi SM, Nazifi S, Rakhshandehroo E, Sanati AR. A study on the status of inflammatory systems in camels naturally infected with *Toxoplasma gondii*. *Trop Anim Health Prod*. 2015;47:909–914.
73. Hoekzema R, Murray PI, van Haren MA, Helle M, Kijlstra A. Analysis of interleukin-6 in endotoxin-induced uveitis. *Invest Ophthalmol Vis Sci*. 1991;32:88–95.
74. Norose K, Yano A, Wang XC, et al. Dominance of activated T cells and interleukin-6 in aqueous humor in Vogt-Koyanagi-Harada disease. *Invest Ophthalmol Vis Sci*. 1994;35: 33–39.
75. Benson MT, Shepherd L, Rees RC, Rennie IG. Production of interleukin-6 by human retinal pigment epithelium *in vitro* and its regulation by other cytokines. *Curr Eye Res*. 1992;11(Suppl.):173–179.
76. Fleisher LN, McGahan MC, Ferrell JB. Rabbit pigmented ciliary epithelium produces interleukin-6 in response to inflammatory cytokines. *Exp Eye Res*. 2000;70:271–279.
77. Mammari N, Vignoles P, Halabi MA, Darde ML, Courtioux B. *In vitro* infection of human nervous cells by two strains of *Toxoplasma gondii*: a kinetic analysis of immune mediators and parasite multiplication. *PLoS ONE*. 2014;9:e98491.
78. Rey A, Molins B, Llorenc V, Pelegrin L, Mesquida M, Adan A. Cytokine profiling reveals decreased serum levels of CCL2 in active ocular toxoplasmosis. *Br J Ophthalmol*. 2013;97:1338–1342.
79. Robben PM, LaRegina M, Kuziel WA, Sibley LD. Recruitment of Gr-1$^+$ monocytes is essential for control of acute toxoplasmosis. *J Exp Med*. 2005;201:1761–1769.
80. Ashander LM, Lie S, Ma Y, et al. Neutrophil activities in human ocular toxoplasmosis: an in vitro study with human cells. *Invest Ophthalmol Vis Sci*. 2019;60:4652–4660.
81. de Araújo TE, Coelho-Dos-Reis JG, Béla SR, et al. Early serum biomarker networks in infants with distinct retinochoroidal lesion status of congenital toxoplasmosis. *Cytokine*. 2017;95:102–112.
82. Channon JY, Miselis KA, Minns LA, Dutta C, Kasper LH. *Toxoplasma gondii* induces granulocyte colony-stimulating factor and granulocyte-macrophage colony-stimulating factor secretion by human fibroblasts: implications for neutrophil apoptosis. *Infect Immun*. 2002;70:6048–6057.
83. Menzies-Gow A, Ying S, Sabroe I, et al. Eotaxin (CCL11) and eotaxin-2 (CCL24) induce recruitment of eosinophils, basophils, neutrophils, and macrophages as well as features of early- and late-phase allergic reactions following cutaneous injection in human atopic and nonatopic volunteers. *J Immunol*. 2002;169:2712–2718.
84. Monaghan KL, Wan ECK. The Role of granulocyte-macrophage colony-stimulating factor in murine models of multiple sclerosis. *Cells*. 2020;9:E611.
85. Abu El-Asrar AM, Struyf S, Opdenakker G, Geboes K, Van Damme J. The role of chemokines and their receptors in uveitis. *Int Ophthalmol*. 2007;27:321–327.
86. Fisson S, Ouakrim H, Touitou V, et al. Cytokine profile in human eyes: contribution of a new cytokine combination for differential diagnosis between intraocular lymphoma or uveitis. *PLoS ONE*. 2013;8:e52385.
87. Ongkosuwito JV, Bosch-Driessen EH, Kijlstra A, Rothova A. Serologic evaluation of patients with primary and recurrent ocular toxoplasmosis for evidence of recent infection. *Am J Ophthalmol*. 1999;128:407–412.

Investigative Ophthalmology & Visual Science

Downloaded from abstracts.iovs.org on 04/26/2024