

Distinct Pathways of Macular Atrophy in Type 3 Macular Neovascularization Associated With AMD

Enrico Borrelli,¹ Costanza Barresi,^{1,2} Federico Ricardi,³ Alessandro Berni,^{1,2} Domenico Grosso,^{1,2} Pasquale Viggiano,⁴ Paola Marolo,³ Ugo Introini,¹ Michele Reibaldi,³ and Francesco Bandello^{1,2}

¹IRCCS San Raffaele Scientific Institute, Milan, Italy

²Vita-Salute San Raffaele University, Milan, Italy

³Department of Ophthalmology, University of Turin, Turin, Italy

⁴Department of Basic Medical Sciences, Neuroscience and Sense Organs, University of Bari "Aldo Moro", Bari, Italy

Correspondence: Enrico Borrelli, Department of Ophthalmology, University Vita-Salute San Raffaele, Via Olgettina 60, Milan 20132, Italy; borrelli.enrico@yahoo.com.

MR and FB contributed equally to the work presented here and should therefore be regarded as equivalent authors.

Received: November 4, 2023

Accepted: February 25, 2024

Published: March 12, 2024

Citation: Borrelli E, Barresi C, Ricardi F, et al. Distinct pathways of macular atrophy in type 3 macular neovascularization associated with AMD. *Invest Ophthalmol Vis Sci*. 2024;65(3):18. <https://doi.org/10.1167/iovs.65.3.18>

PURPOSE. To explore the occurrence of macular atrophy (MA) in eyes with age-related macular degeneration (AMD)-associated Type 3 macular neovascularization (MNV) treated with anti-vascular endothelial growth factor (anti-VEGF) therapy. Importantly, we aimed at describing the existence of separate pathways leading to MA.

METHODS. We analyzed 41 participants (41 eyes) with treatment-naïve Type 3 MNV who were followed up for a duration of 12 months after beginning the anti-VEGF therapy. At the one-year follow-up visit, optical coherence tomography (OCT) scans were reviewed for the presence of MA. MA regions of interest (ROIs) were selected and traced back to their original dominant baseline lesion (i.e., precursor) through previous serially captured OCT scans. Baseline lesions included precursors associated with the development and exudation of MNV and causes external to the neovascularization itself.

RESULTS. At the one-year follow-up visit, MA was graded to be present in 38 (92.7%) out of 41 eyes. These 78 MA ROIs were divided into two subgroups according to the precursor lesion, yielding a group of 53 MA lesions with precursors associated with the development and exudation of MNV (i.e., MA caused by physical harm from Type 3 neovessels, collapse of a serous pigment epithelium detachment, and fibrosis) and 25 MA regions with precursors external to the neovascularization itself (i.e., MA caused by drusen or subretinal drusenoid deposits).

CONCLUSIONS. Eyes with Type 3 MNV are commonly complicated by MA and precursors of MA include causes associated with the development and exudation of MNV, as well as lesions unrelated to the neovascularization process itself.

Keywords: age-related macular degeneration, neovascularization, macular degeneration

Neovascular exudative age-related macular degeneration (AMD) is a prevalent reason for vision loss in individuals aged 50 and above.¹ In AMD patients, the development of a macular neovascularization (MNV) and subsequent exudation can lead to a decline in visual acuity.² These neovessels may arise from either the choroid (Type 1 and Type 2) or the retina (Type 3). Initially, Type 3 MNV was termed "retinal vascular abnormality" or "retinal vascular anomalous complex."³ Later, Yannuzzi and Negrão⁴ introduced the term "retinal angiomatous proliferation" (RAP) for this lesion, which is now commonly referred to as Type 3 MNV.⁵⁻⁹

Despite the significant improvement in visual outcomes for patients with exudative neovascular AMD caused by anti-vascular endothelial growth factor (VEGF) therapy's ability to resolve exudation, there are potential macular complications such as fibrosis, subretinal hemorrhage, and macular

atrophy (MA) that can arise and significantly affect clinical outcomes.¹⁰⁻¹⁵

Researchers have proposed using the term "macular atrophy" to describe regions of retinal pigment epithelium (RPE) atrophy and the loss of photoreceptors, regardless of whether this complication is linked to MNV.¹² On the other hand, the term "geographic atrophy" (GA) is generally reserved for cases without any associated exudative MNV.¹⁶ Previous significant research using color photographs and fundus autofluorescence (FAF) images revealed that 40% of the eyes exhibited MA at the onset of MNV, and approximately half of these cases were attributed to pre-existing GA.¹² Moreover, neovascular AMD eyes with evidence of MA experienced worse visual outcomes compared with those without this complication.^{12,17}

Structural optical coherence tomography (OCT) plays a crucial role in assessing patients with neovascular AMD by



providing detailed anatomical information. It is particularly valuable for identifying signs of exudation and detecting macular complications, including MA.^{17–19} A recent study by Staurengi et al.¹⁸ retrospectively analyzed the structural OCT findings of neovascular AMD patients treated in the HARBOR trial. The researchers aimed to establish correlations between baseline characteristics and the development of MA during the follow-up period. Notably, the study's post-hoc analysis revealed that Type 3 MNV in the study eye was a strong risk factor for the development of MA at the 24-month follow-up visit.

In this longitudinal study over one year of follow-up, we assessed the development of MA in a cohort of eyes with newly diagnosed AMD-associated Type 3 MNV treated with anti-vascular endothelial growth factor (anti-VEGF) therapy. Furthermore, when examining lesions instead of the entire eyes, we suggest a straightforward concept that suggests the existence of separate pathways leading to MA in patients with Type 3 MNV. These pathways might manifest independently or in combination within a single eye.

METHODS

This was a multicenter, retrospective observational case series that adhered to the tenets of the Declaration of Helsinki. All patients involved signed an informed consent form approved by the local Ethics Committees.

Subjects

The authors in this study identified patients with AMD and treatment-naïve Type 3 MNV as determined by clinical examination, structural OCT, OCT angiography (OCTA), and angiography tests (i.e., fluorescein angiography and indocyanine green angiography).^{6,7,19–21} All patients had undergone either OCTA or angiography tests at baseline to be included. In structural OCT, Type 3 MNV appeared as a hyper-reflective lesion situated in the outer retina, extending toward a drusenoid or serous pigment epithelium detachment (PED). This lesion exhibited detectable flow on OCTA. Fluorescein angiography revealed a retinal arteriole bending toward the RPE, accompanied by intraretinal leakage and subretinal leakage/pooling. Indocyanine green angiography displayed a retinal arteriole bending toward the RPE, featuring a hyperfluorescent hot spot and late leakage. Once a diagnosis of exudative Type 3 MNV was established, all patients were administered a loading dose of anti-VEGF intravitreal injections, and, subsequently, the patients were subjected to either an as-needed approach or a treat-and-extend regimen at the discretion of the treating physician.

To be included in the study, the patients needed to be followed up for a duration of 12 months after beginning the anti-VEGF therapy. Throughout this period, the eyes were regularly examined using OCT scans. These scans were performed at least six times over the course of the 12 months, because the primary objective was to evaluate how frequently MA developed within the eyes over the course of one year and to trace precursor lesions of MA.

The criteria for excluding individuals from the study were as follows: (i) the presence of concomitant Type 1 or 2 MNV, (ii) the existence of fibrosis at baseline, determined through fundus examination and structural OCT assessment,¹⁰ (iii) indications of RPE tear,¹¹ (iv) prior history of vitreoretinal surgery in the eye under study, and (v) the presence of other

disorders affecting the macula or optic nerve. All patients underwent a complete ophthalmological assessment including structural OCT. This imaging was conducted using the Heidelberg Spectralis HRA + OCT (Heidelberg Engineering, Heidelberg, Germany) spectral domain device.

OCT Assessment

The spectral domain OCT imaging session included 19 horizontal B-scans covering approximately a 5.5×4.5 mm area centered on the fovea. Every B-scan consisted of an average of 25 OCT images and images were acquired with a high-resolution mode. For inclusion, the OCT images needed to have a signal strength of at least 25 dB, as per the manufacturer's suggestion.²²

An experienced and certified grader (E.B.) initially assessed the eligibility of structural OCT images. Subsequently, two independent graders (C.B. and F.R.) examined OCT images at the one-year follow-up visit for the presence of MA, which was defined using modified Classification of Atrophy Meetings definitions.²³ In details, MA was graded to be present when a complete RPE and outer retinal atrophy (cRORA) was detected.²³ The Classification of Atrophy Meetings group defined cRORA as an area characterized by hypertransmission spanning at least 250 μ m in diameter, accompanied by a zone of RPE attenuation or disruption of at least 250 μ m in diameter, along with evident photoreceptor degeneration. Importantly, these features are observed without any indication of an RPE tear. Each MA was treated as a distinct region of interest (ROI) and traced back to its original dominant baseline lesion (i.e., precursor) through previous serially captured OCT scans.

In cases where MA lesions were already visible during the visit when the first signs of exudative Type 3 MNV appeared, the OCT scans preceding this visit were also assessed and included in the analysis. This was available for all included subjects. Conversely, in cases where MA lesions developed within the first year after the onset of MNV, there was no need to examine visits before the baseline assessment. In other words, we retrospectively reviewed visits, including those before the baseline assessment if needed, until we were confident in identifying the MA precursor. If an eye had an ROI where establishing the baseline precursor was not feasible because of the existence of this MA lesion before the earliest accessible examination, this eye was not included in the analysis.

Baseline lesions included precursors associated with the development and exudation of MNV (i.e., see the "Results" section for details). Conversely, causes external to the neovascularization itself included drusen and subretinal drusenoid deposits (SDDs), as previously demonstrated.²⁴ Some eyes exhibited ROIs in multiple categories. The whole grading process was conducted independently by the two graders (C.B. and F.R.), and any differences in assessment were openly resolved between them. To conclude the grading process and reach a final reading outcome, an experienced and certified grader (E.B.) finally evaluated all prior grading that was previously conducted and confirmed previous grading results after an open discussion with the two graders. The experienced and certified grader modified the grading in five out of 78 cases. After the latter grading was completed, the same grader (E.B.) graded images at the visit with first evidence of Type 3 MNV to classify the neovascularization on the basis of the staging system proposed by Su and colleagues.²⁰

Statistical Analysis

Statistical analysis was performed using Statistical Package for Social Sciences (28.0.1.0 version; IBM, Armonk, NY, USA). All quantitative variables were reported as mean and standard deviation (SD) in the “Results” section and Table. Paired-samples *t* test and Fischer’s exact test were conducted to compare quantitative and qualitative variables, respectively, at baseline and follow-up visits. The chosen level of statistical significance was $P < 0.05$.

RESULTS

Baseline Patients’ Characteristics

Forty-one patients (41 eyes) were enrolled in this study. Mean \pm SD age was 80.0 ± 6.9 years (range 66–96 years). Twenty-two (53.7%) fellow eyes displayed evidence of exudative neovascular AMD (i.e., 18 eyes with Type 3 MNV and four eyes with Type 1 MNV), whereas five (12.2%) and 14 (34.1%) fellow eyes exhibited findings consistent with GA and early/intermediate AMD, respectively.²

At baseline, 2 (4.8%) study eyes exhibited intraretinal hyper-reflective lesions with IRF and without external limiting membrane/ellipsoid zone disruption. These later observations matched the characteristics of stage 1 Type 3 MNV (Table).²⁰ In 4 out of 41 (9.8%) of the study eyes, neovessels were associated with IRF and outer retinal disruption without RPE disruption, the latter findings consistent with stage 2 Type 3 MNV not reaching the RPE (Table).²⁰ The remaining 35 (85.4%) eyes were graded to have features consistent with stage 2 Type 3 MNV reaching the RPE or stage 3 Type 3 MNV,²⁰ as in these cases the Type 3 lesions extended until the RPE (i.e., stage 2 Type 3 MNV reaching the RPE) or into the sub-RPE space (i.e., stage 3 Type 3 MNV). Mean \pm SD number of anti-VEGF injections during the study period was 7.6 ± 1.3 . Thirty eyes underwent treatment following a treat and extend regimen, whereas eleven eyes were treated using an as-needed regimen.

Longitudinal Functional and Morphological Changes

Visual acuity was 0.42 ± 0.29 LogMAR (Snellen equivalent of approximately 20/50) in the study eyes at baseline and 0.20 ± 0.22 LogMAR (Snellen equivalent of approximately 20/32) at the one-year follow-up visit ($P < 0.0001$) (Table). On structural OCT, IRF was graded to be present in

41 (100.0%) and 13 (31.7%) eyes at baseline and one-year follow-up visits, respectively (Table). Similarly, the presence of SRF was confirmed in 20 (48.8%) eyes at baseline and one (2.4%) eye at the one-year follow-up visit (Table).

Macular Atrophy Assessment

At the one-year follow-up visit, MA was graded to be present in 38 (92.7%) out of 41 eyes. Among these 38 eyes with MA at the one-year follow-up visit, 13 had evidence of MA before the development of Type 3 MNV.

Overall, 78 regions of MA were graded to be present in the whole cohort of study eyes. The average number of MA lesions for each eye was 1.9 ± 1.2 (range 0–5) at the one-year follow-up visit.

These 78 regions of MA that were detected at the one-year follow-up visit were divided into two subgroups according to the precursor lesion, yielding a group of 53 MA lesions with precursors associated with the development and exudation of MNV (i.e., MNV-related MA) and 25 MA regions with precursors external to the neovascularization itself (i.e., MNV-unrelated MA). Moreover, 18 (45.2%) out of 38 eyes had MA lesions secondary to MNV-related precursors, whereas two (7.2%) eyes had MA lesions secondary to MNV-unrelated precursors, and 18 (47.6%) eyes had MA lesions secondary to both MNV-related and -unrelated precursors.

MNV-Related Macular Atrophy

As mentioned above, 53 (67.9%) out of 78 regions were graded to be associated with MNV-related precursors. In details, our grading process revealed that precursors associated with the development and exudation of MNV included the following:

Neovessels Causing a Mechanical Damage to the RPE. The intrusion of neovessels into the sub-RPE space resulted in mechanical harm to the RPE (Fig. 1). The extent of RPE atrophy observed in this scenario fairly matches the dimensions of the intraretinal hyper-reflective lesion, which corresponds to the neovascularization crossing through the RPE, leading to the inflicted mechanical damage. Twenty-two (41.5%) out of 53 MA lesions in 21 eyes were graded to be mainly associated with a mechanical damage to the RPE.

Collapse of a Serous PED. Serous PEDs may be frequently associated with Type 3 MNV as a result of neovascular exudation beneath the RPE (Fig. 2).²⁰ Serous PEDs demonstrate a hyporeflexive, optically empty

TABLE. Clinical and Morphologic Characteristics at the Baseline and Follow-Up Visits

Characteristic	Visits		P Value
	Baseline Visit (First Evidence of Exudative Type 3 MNV)	1-Year Follow-Up Visit	
Visual acuity (LogMAR), mean (SD)	0.42 (0.29)	0.20 (0.22)	<0.0001*
Type 3 MNV stage		—	—
Stage 1	2 (4.8%)	—	—
Stage 2 without RPE involvement	4 (9.8%)	—	—
Stage 2 with RPE involvement or Stage 3	35 (85.4%)	—	—
Intraretinal fluid	41 (100%)	13 (31.7%)	—
Subretinal fluid	20 (48.8%)	1 (2.4%)	—
Subretinal drusenoid deposits	25 (61.0%)	—	—

Quantitative values are expressed in mean \pm SD (standard deviation).

*Paired-samples *t* test.

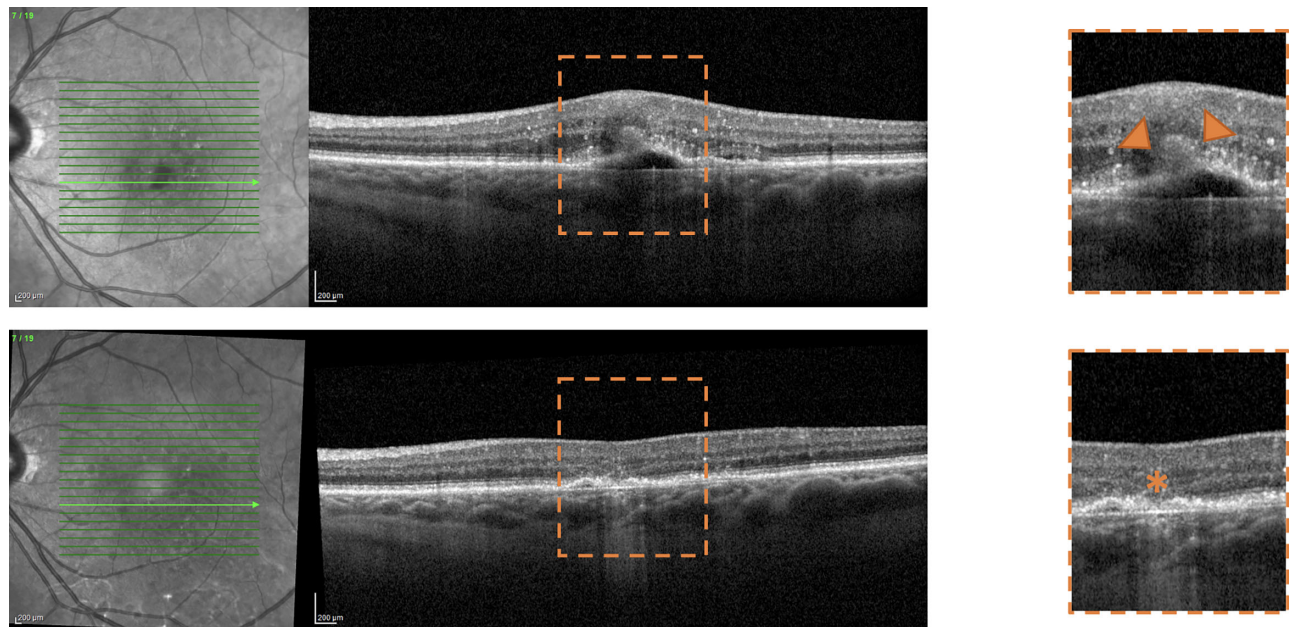


FIGURE 1. Representative optical coherence tomography (OCT) B-scans of a patient with Type 3 MNV developing macular atrophy associated with neovessels causing a mechanical damage to the RPE. *Top row:* Visit with first evidence of treatment-naïve exudative Type 3 MNV. *Bottom row:* Twelve-month follow-up visit after the initiation of anti-vascular endothelial growth factor (anti-VEGF) therapy. OCT B-scan (*top*) shows the presence of an intraretinal hyper-reflective lesion (*orange arrowheads*) reaching the RPE/sub-RPE space. This hyper-reflective lesion corresponds to the invading neovascularization through the outer retina and RPE, leading to the inflicted mechanical damage. At the one-year follow-up visit, a region of macular atrophy is detected (*orange asterisk*). The extent of RPE atrophy observed in this scenario fairly matches the dimensions of the intraretinal hyper-reflective lesion. A magnified visualization of this region of interest is reported on the right.

space between the RPE and Bruch's membrane. After the resolution or reduction of the fluid leakage, serous PEDs might collapse, leading to atrophy of the RPE. This atrophy typically extends beyond the dimensions of the hyper-reflective lesion within the retina, which corresponds to the neovascular lesion. Twenty (37.7%) out of 53 MA lesions in 13 eyes were graded to be mainly associated with a serous PED collapse.

Fibrosis. The development of fibrosis resulted in RPE atrophy in a number of cases. Fibrosis is typically defined on OCT as hyper-reflective material, either in the subretinal or sub-RPE space, associated with a well delineated mound of white-yellowish tissue on fundus examination.²⁵ Eleven (20.7%) out of 53 MA lesions in 10 eyes were graded to be mainly associated with development of fibrosis.

MNV-Unrelated Macular Atrophy

Twenty-five (32.0%) out of 78 regions were graded to be associated with MNV-unrelated precursors (Fig. 3). As stated above, precursors external to the neovascularization itself included drusen and SDDs, as previously suggested.²⁴ In details, 24 MA lesions were drusen-associated, whereas only one MA lesion was found to have developed within a region with SDDs. Last, 14 (56.0%) out of 25 MA lesions secondary to MNV-unrelated precursors were graded to have developed before the occurrence of Type 3 MNV.

DISCUSSION

In this study, we described the occurrence and characteristics of macular atrophy in a study cohort of individuals

with treatment-naïve AMD-associated exudative Type 3 MNV. These patients received intravitreal anti-VEGF therapy and were observed for a duration of 1 year. MA was graded to be present when a cRORA was detected.²³ Overall, results of the present study demonstrated that eyes with Type 3 MNV may be commonly complicated by MA. Notably, we identified distinct pathways leading to MA in these eyes. This finding implies that various disease mechanisms might contribute to the formation and progression of RPE atrophy in the context of Type 3 MNV.

Macular atrophy is a common complication that may be observed in eyes with neovascular AMD and is typically associated with worse visual outcomes.^{12,17} As noted above, Staurengi et al.¹⁸ retrospectively analyzed the structural OCT findings of neovascular AMD patients treated in the HARBOR trial and demonstrated that Type 3 MNV in the study eye is a relevant risk factor for development of MA at the 24-month follow-up visit. In details, of the 1097 patients participating in the HARBOR trial, 177 individuals had evidence of Type 3 MNV.¹⁸ Among these, 27 patients (15.3%) with Type 3 MNV displayed signs of MA in the study eye at baseline (i.e., before the initiation of anti-VEGF therapy).¹⁸ In cases with no detectable MA at baseline, 49.2% of these cases developed new MA by month 24.¹⁸ In total, when considering both patients with existing atrophy before treatment and those who developed atrophy during the course of treatment, approximately two out of three patients with Type 3 MNV experienced MA within two years.¹⁸ Similarly, Baek et al.²⁶ investigated the incidence of MA in a study on 73 eyes with AMD and exudative Type 3 MNV. In the latter study, the authors showed that approximately 60% developed MA at year 3. Finally, the latter observations aligned with the outcomes of the CATT trial, which similarly

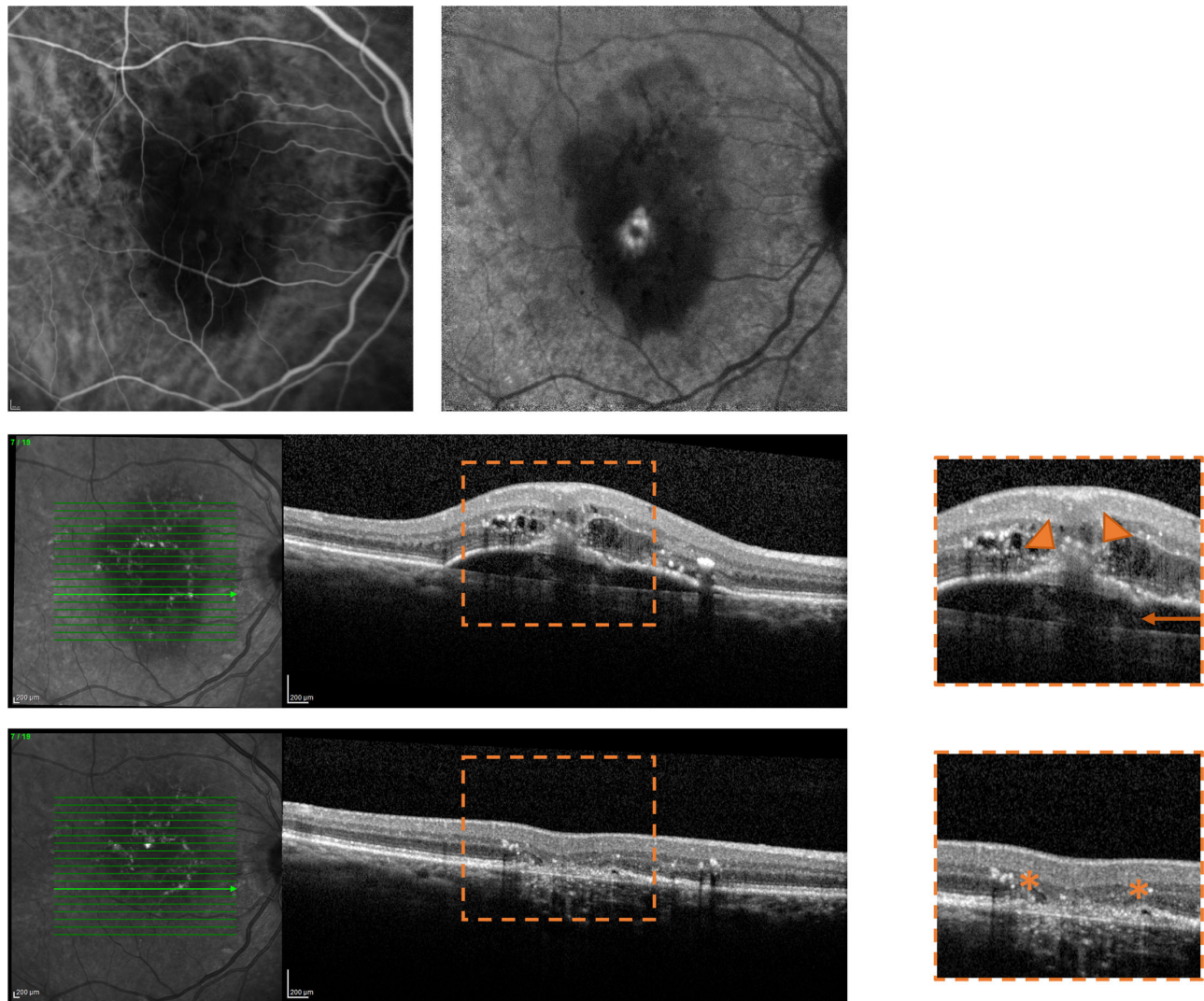


FIGURE 2. Representative images of a patient with Type 3 MNV developing macular atrophy secondary to collapse of a serous pigment epithelium detachment (PED). *Top row:* visit with first evidence of treatment-naïve exudative Type 3 MNV; early and late indocyanine green angiography (ICGA) images show an early hot spot with late leakage. *Middle row:* visit with first evidence of treatment-naïve exudative Type 3 MNV. *Bottom row:* Twelve-month follow-up visit after the initiation of anti-VEGF therapy. (*Middle and bottom rows*) OCT B-scan (*middle row*) shows the presence of an intraretinal hyper-reflective lesion (*orange arrowheads*) reaching the RPE/sub-RPE space and determining the formation of a serous PED (*orange arrow*). At the one-year follow-up visit, a region of macular atrophy was detected (*orange asterisks* at the margins of this region). In this case, MA was graded to be secondary to collapse of the serous PED previously detected (i.e., multimodal imaging excluded the presence of an associated Type 1 MNV). This atrophy typically extends beyond the dimensions of the hyper-reflective lesion within the retina. A magnified visualization of this region of interest is reported on the right.

indicated that Type 3 MNV carries an increased likelihood of MA development.²⁷

Consistently, in our study cohort of eyes with treatment-naïve Type 3 MNV at baseline, MA was detected in 31.7% of patients at baseline. Among cases where MA was not initially observable, approximately 90% of these cases developed new MA within a 1-year follow-up period. As a result, the occurrence of MA in our study group seems to be higher compared to previous reports.^{18,26} This could be attributed to the majority of our patients (85.4% or 35 out of 41) displaying evidence of stage 2 with RPE disruption or stage 3 Type 3 MNV.²⁰ Assuming that Type 3 lesions extend until the RPE at this stage, it is plausible that this may result in mechanical harm to the RPE, potentially explaining the increased incidence of MA in our study cohort. Additionally, although Baek and colleagues²⁶ excluded cases with fibrosis

from their analysis, we did not exclude such cases because fibrosis is often associated with atrophy development,²⁵ and our main objective was to explore MA patterns in Type 3 MNV eyes. Last, the ability to detect MA relies on the quality of OCT images, and the use of averaged OCT images might have enhanced our ability to identify these types of lesions.

Although the above-mentioned previous studies have examined the occurrence of MA in patients with Type 3 MNV in exudative neovascular AMD,^{18,26} these reports did not investigate the mechanisms that may contribute to the development of MA in such cases. The correlation between MNV Type 3 and MA was speculated to be related to the presence of SDDs, given their prevalence in Type 3 MNV-affected eyes and their established role as a risk factor for RPE atrophy.¹⁸ Alternatively, it was supposed that the progression toward atrophy might also be influenced by a more pronounced

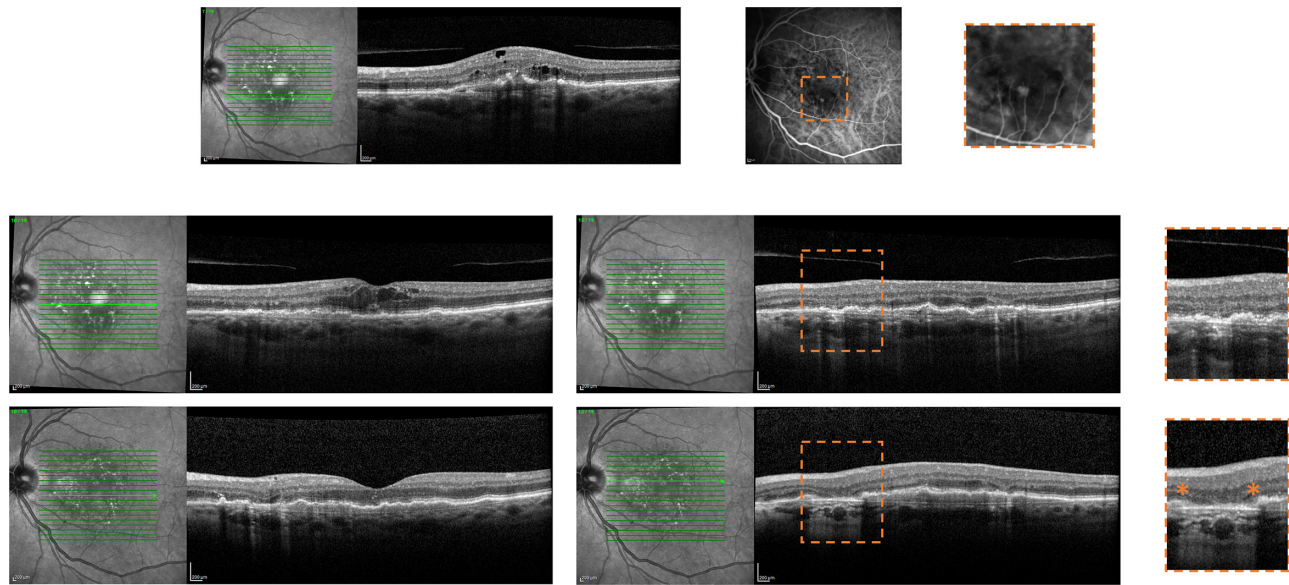


FIGURE 3. Representative images of a patient with Type 3 MNV developing drusen-associated macular atrophy. *Top row:* Visit with first evidence of treatment-naïve exudative Type 3 MNV; structural OCT B-scan passing through the Type 3 MNV shows an intraretinal hyper-reflective lesion. The early phase indocyanine green angiography image displays the fluorescent intraretinal neovascularization. *Middle row:* Visit with first evidence of treatment-naïve exudative Type 3 MNV. *Bottom row:* Twelve-month follow-up visit after the initiation of anti-VEGF therapy. (*Middle and bottom rows*) OCT B-scans through the fovea (left column) shows the presence of exudative intraretinal fluid that resolved after 1 year of treatment. At the follow-up visit, a region of macular atrophy (cRORA) was graded to be present in the perifoveal superonasal region (*middle column*). This region was secondary to iRORA (i.e., the extent of RPE and photoreceptor loss measures less than 250 μm in length) and contiguous drusen collapse, as evident by tracing this region back through the previous visits. A magnified visualization of this region of interest is reported on the right.

impairment of the choriocapillaris blood flow.^{18,28,29} To gain clarity on this important aspect, we traced the individual regions of MA in prior serial eye-tracked structural OCT scans back to their dominant precursor lesions. Overall, these lesions included precursors associated with the development and exudation of MNV (i.e., MA caused by physical harm from Type 3 neovessels, collapse of a serous PED, and fibrosis) and causes unrelated to the neovascularization process itself (i.e., RPE atrophy secondary to drusen or SDDs). Recognizing precursors of MA holds significance, because diverse treatment strategies might be applied to mitigate the onset and advancement of atrophy based on the underlying causes.

Retinal imaging has greatly expanded our comprehension of Type 3 MNV, and previous studies have demonstrated that this neovascular lesion originates from the deep vascular complex and extends downward toward the RPE, possibly leading to exudation.^{8,20,30–32} In details, exudative Type 3 MNV may have a preceding stage where a precursor lesion exists without leakage. This precursor lesion is commonly seen on structural OCT as an intraretinal hyper-reflective focus above the external limiting membrane.³³ In a few cases, neovessels might exhibit leakage before causing disruption in the outer retinal layers (referred to as stage 1 Type 3 MNV).²⁰ Most commonly, before leading to exudation, neovessels progress through the outer retinal layers, gradually disrupting them. Ultimately, they reach the RPE or sub-RPE space, resulting in the physical disruption of the RPE, which is present in most cases as displayed by Matsumoto and colleagues.³⁴ This damage is the hallmark of most stage 2 Type 3 MNV cases and all stage 3 Type 3 MNV cases.²⁰ Consequently, this RPE damage frequently leads to an area of MA, as indicated by our findings. The extent of

RPE atrophy observed in this scenario aligns with the dimensions of the intraretinal hyper-reflective lesion, corresponding to the neovascular structures penetrating the RPE and causing the inflicted mechanical harm.

Along with the development of intraretinal fluid and RPE disruption, when neovessels reach the RPE/sub-RPE, space may frequently exudate beneath the RPE, determining the formation of a new serous PED or a mixed PED by vascularizing and exudating within an existing drusenoid PED.²⁰ In our series, we showed that after the resolution or reduction of the fluid leakage, a number of serous PEDs collapse, leading to atrophy of the RPE. This atrophy typically extends beyond the dimensions of the hyper-reflective lesion within the retina, which corresponds to the neovascular structure. In this scenario, the size of the MA may either match or be smaller than that of the serous PED.

Fibrosis is a severe complication that may arise in eyes affected by neovascular AMD, often leading to unfavorable long-term visual outcomes.²⁵ Although the occurrence of fibrosis is more frequent in other types of MNV (i.e., Type 2 MNV), it can also manifest in eyes with Type 3 MNV.³⁵ In cases of Type 3 MNV, there is a tendency for atrophy to develop over fibrosis, as the latter can impede the delivery of oxygen and nutrients from the choroid to the RPE and outer retina.³⁶ Our analysis corroborated that fibrosis might be accountable for MA in several cases of Type 3 MNV.

As mentioned above, MA developing in eyes with AMD and Type 3 MNV may be also secondary to causes unrelated to the neovascularization process itself. In dry AMD eyes, the principal precursor lesions of RPE atrophy (i.e., named GA in these eyes) are drusen and SDDs, which represent the two distinct lesions of intermediate AMD.^{24,37} The latter two lesions may cause RPE atrophy prior to the emergence of

Type 3 MNV and, consequently, a number of regions of MA may actually appear before the occurrence of Type 3 MNV, similar to what we observed in our study. Alternatively, these precursor lesions may progress over time independently of the development of neovascularization and eventually lead to RPE atrophy after the development of Type 3 MNV (i.e., referred to as MA in this context). The results of the present study appear to support the hypothesis that MA can develop because of the progression of these precursor lesions over time. This suggests that the development of MA in cases of Type 3 MNV might not be solely attributed to the presence of neovascularization but could be influenced by the progression of these precursor lesions as well.

The complement system appears to be involved in the GA pathogenesis and progression,^{38,39} and intravitreal therapies with complement inhibitors have been recently approved by the United States Food and Drug Administration for the treatment of GA. Future studies may clarify whether these therapeutic approaches might offer advantages in diminishing the occurrence and advancement of MA linked to drusen and SDDs in eyes with Type 3 MNV.

Our study has limitations that should be weighed when interpreting our results. The main limitation of our study was that our study cohort was not part of a large multicenter trial, and included subjects did not undergo regular follow-up visits with consistent intervals. Moreover, although a number of regions of MA were graded to be secondary to precursors unrelated to the neovascularization process itself (i.e., drusen and SDDs), we are not able to exclude the possibility that exudation processes might have triggered the progression of these lesions into atrophy. Importantly, our one-year follow-up from the baseline might have restricted our ability to detect MAs associated with drusen and SDDs, as these lesions may require more time to initiate atrophy. Conversely, we believe that a substantial number of MAs resulting from MNV and exudation tend to appear earlier within the first year. Consequently, there is a possibility that we have overestimated the number of MNV-associated MAs while underestimating those associated with drusen and SDDs. Finally, the spacing between B-scans in the protocol was approximately 240 μm , which could have limited our assessment. Specifically, regions of the RPE atrophy graded with sizes below 250 μm might have actually been larger since their boundaries frequently extended across two consecutive scans. Nevertheless, the study's main purpose was to distinguish various patterns contributing to MA in Type 3 MNV. We used tracked OCT images, enabling us to pursue this primary objective.

In summary, the present study confirmed that eyes with Type 3 MNV may be commonly complicated by macular atrophy. Importantly, we identified distinct pathways leading to MA in these eyes. Precursors of MA included causes associated with the development and exudation of MNV, as well as lesions unrelated to the neovascularization process itself. Our findings appear to suggest that various disease mechanisms might contribute to the formation and progression of RPE atrophy in the context of Type 3 MNV.

Acknowledgments

Disclosure: **E. Borrelli**, Abbvie (C), Bayer (C), Hofmann La Roche (C), Zeiss (C); **C. Barresi**, None; **F. Ricardi**, None; **A. Berni**, None; **D. Grosso**, None; **P. Viggiano**, None; **P. Marolo**, None; **U. Introini**, None; **M. Reibaldi**, Abbvie (C), Bayer (C), Hofmann La Roche (C), Novartis (C); **F. Bandello**, Abbvie (C),

Alimera (C), Bayer (C), Boehringer-Ingelheim (C), Fidia Sooft (C), Hofmann La Roche (C), Novartis (C), Ntc Pharma (C), Oxurion Nv (C), Sifi (C)

References

- Friedman DS, O'Colmain BJ, Muñoz B, et al. Prevalence of age-related macular degeneration in the United States. *Arch Ophthalmol*. 2004;122:564–572.
- Ferris FL, Wilkinson CP, Bird A, et al. Clinical classification of age-related macular degeneration. *Ophthalmology*. 2013;120:844–851.
- Hartnett ME, Weiter JJ, Staurengi G, Elsner AE. Deep retinal vascular anomalous complexes in advanced age-related macular degeneration. *Ophthalmology*. 1996;103:2042–2053.
- Yannuzzi LA, Negrão S. Retinal angiomatous proliferation in age-related macular degeneration. *Retina*. 2001;21:416–434.
- Yannuzzi LA, Freund KB, Takahashi BS. Review of retinal angiomatous proliferation or type 3 neovascularization. *Retina*. 2008;28:375–384.
- Freund KB, Ho I-V, Barbazetto IA, et al. Type 3 neovascularization: the expanded spectrum of retinal angiomatous proliferation. *Retina*. 2008;28:201–211.
- Freund KB, Zweifek S, Engelbert M. Do we need a new classification for choroidal neovascularization in age-related macular. *Retina*. 2010;30:1333–1349.
- Borrelli E, Mastropasqua L, Souied E, et al. Longitudinal assessment of type 3 macular neovascularization using 3D volume-rendering OCTA. *Can J Ophthalmol*. 2022;57:228–235.
- Borrelli E, Sacconi R, Klose G, et al. Rotational three-dimensional OCTA: a notable new imaging tool to characterize type 3 macular neovascularization. *Sci Rep*. 2019;9(1):17053.
- Querques L, Parravano M, Borrelli E, et al. Anatomical and functional changes in neovascular AMD in remission: comparison of fibrocellular and fibrovascular phenotypes. *Br J Ophthalmol*. 2020;104:47–52.
- Barresi C, Borrelli E, Fantaguzzi F, et al. Complications associated with worse visual outcomes in patients with exudative neovascular age-related macular degeneration. *Ophthalmologica*. 2021;244:512–522.
- Domalpally A, Danis RP, Trane R, et al. Atrophy in neovascular age-related macular degeneration: age-related eye disease study 2 report number 15. *Ophthalmol Retina*. 2018;2:1021–1027.
- Borrelli E, Bandello F, Souied EH, et al. Neovascular age-related macular degeneration: advancement in retinal imaging builds a bridge between histopathology and clinical findings. *Graefes Arch Clin Exp Ophthalmol*. 2022;260:2087–2093.
- Barresi C, Chhablani J, Dolz-Marco R, et al. Retinal neurodegeneration in age-related macular degeneration [published online ahead of print July 2, 2023]. *Eur J Ophthalmol*. doi:10.1177/11206721231186166.
- Miere A, Querques G, Semoun O, et al. Optical coherence tomography angiography changes in early type 3 neovascularization after anti-vascular endothelial growth factor treatment. *Retina*. 2017;37:1873–1879.
- Abdelfattah NS, Al-Sheikh M, Pitetta S, et al. Macular atrophy in neovascular age-related macular degeneration with monthly versus treat-and-extend ranibizumab: findings from the TREX-AMD Trial. *Ophthalmology*. 2017;124:215–223.
- Fang M, Chanwimol K, Maram J, et al. Morphological characteristics of eyes with neovascular age-related macular degeneration and good long-term visual outcomes after anti-VEGF therapy. *Br J Ophthalmol*. 2023;107:399–405.

18. Staurengi G, Cozzi M, Sadda S, et al. Characteristics that correlate with macular atrophy in ranibizumab-treated patients with neovascular age-related macular degeneration. *Ophthalmol Retina*. 2023;7:300–306.
19. Nagiel A, Sarraf D, Sadda SR, et al. Type 3 neovascularization evolution, association with pigment epithelial detachment, and treatment response as revealed by spectral domain optical coherence tomography. *Retina*. 2015;35:638–647.
20. Su D, Lin S, Phasukkijwatana N, et al. An updated staging system of type 3 neovascularization using spectral domain optical coherence tomography. *Retina*. 2016;36(Suppl 1):S40–S49.
21. Borrelli E, Barresi C, Lari G, et al. Capturing the transition from intermediate to neovascular AMD: longitudinal inner retinal thinning and factors associated with neuronal loss. *Invest Ophthalmol Vis Sci*. 2023;64:21.
22. Huang Y, Gangaputra S, Lee KE, et al. Signal quality assessment of retinal optical coherence tomography images. *Invest Ophthalmol Vis Sci*. 2012;53:2133–2141.
23. Sadda SRSR, Guymier R, Holz FGFG, et al. Consensus definition for atrophy associated with age-related macular degeneration on OCT: classification of Atrophy Report 3. *Ophthalmology*. 2018;125:537–548.
24. Wei W, Mazzola M, Otero-Marquez O, et al. Two potentially distinct pathways to geographic atrophy in age-related macular degeneration characterized by quantitative fundus autofluorescence. *Eye*. 2023;37:2281–2288.
25. Cheong KX, Cheung CMG, Teo KYC. Review of fibrosis in neovascular age-related macular degeneration. *Am J Ophthalmol*. 2023;246:192–222.
26. Baek J, Lee JH, Kim JY, et al. Geographic atrophy and activity of neovascularization in retinal angiomatous proliferation. *Invest Ophthalmol Vis Sci*. 2016;57:1500.
27. Grunwald JE, Daniel E, Huang J, et al. Risk of geographic atrophy in the comparison of age-related macular degeneration treatments trials. *Ophthalmology*. 2014;121:150–161.
28. Borrelli E, Uji A, Sarraf D, Sadda SR. Alterations in the choriocapillaris in intermediate age-related macular degeneration. *Invest Ophthalmol Vis Sci*. 2017;58:4792–4798.
29. Borrelli E, Souied EH, Freund KBB, et al. Reduced choriocapillaris flow in eyes with type 3 neovascularization due to age-related macular degeneration. *Retina*. 2018;38:1968–1976.
30. Miere A, Querques G, Semoun O, et al. Optical coherence tomography angiography in early type 3 neovascularization. *Retina*. 2015;35:2236–2241.
31. Nagiel A, Sarraf D, Sadda SR, et al. Type 3 neovascularization: evolution, association with pigment epithelial detachment, and treatment response as revealed by spectral domain optical coherence tomography. *Retina*. 2015;35:638–647.
32. Phasukkijwatana N, Tan ACS, Chen X, et al. Optical coherence tomography angiography of type 3 neovascularisation in age-related macular degeneration after antiangiogenic therapy. *Br J Ophthalmol*. 2017;101:597–602.
33. Sacconi R, Sarraf D, Sadda SR, et al. Nascent geographic atrophy as a predictor of type 3 macular neovascularization development. *Ophthalmol Retina*. 2023;7:586–592.
34. Matsumoto H, Sato T, Kishi S. Tomographic features of intraretinal neovascularization in retinal angiomatous proliferation. *Retina*. 2010;30:425–430.
35. Souied EH, Addou-Regnard M, Ohayon A, et al. Spectral-domain optical coherence tomography analysis of fibrotic lesions in neovascular age-related macular degeneration. *Am J Ophthalmol*. 2020;214:151–171.
36. Mehta A, Steel DH, Muldrew A, et al. Associations and outcomes of patients with submacular hemorrhage secondary to age-related macular degeneration in the IVAN Trial. *Am J Ophthalmol*. 2022;236:89–98.
37. Viggiano P, Toto L, Ferro G, et al. Choroidal structural changes in different intermediate AMD patterns. *Eur J Ophthalmol*. 2022;32:460–467.
38. Grassmann F, Harsch S, Brandl C, et al. Assessment of novel genome-wide significant gene loci and lesion growth in geographic atrophy secondary to age-related macular degeneration. *JAMA Ophthalmol*. 2019;137:867–876.
39. Liao DS, Grossi FV, El Mehdi D, et al. Complement C3 inhibitor pegcetacoplan for geographic atrophy secondary to age-related macular degeneration: a randomized phase 2 trial. *Ophthalmology*. 2020;127:186–195.