

Early Single-Examination Optical Coherence Tomography Biomarkers for Treatment-Requiring Retinopathy of Prematurity

Xi Chen,¹ Shwetha Mangalesh,¹ Jocelyn He,² Katrina P. Winter,¹ Vincent Tai,¹ Cynthia A. Toth,¹ and Gui-Shuang Ying²

¹Department of Ophthalmology, Duke University Eye Center, Durham, North Carolina, United States

²Center for Preventive Ophthalmology and Biostatistics, University of Pennsylvania, Philadelphia, Pennsylvania, United States

Correspondence: Xi Chen, Department of Ophthalmology, Duke University Eye Center, 2351 Erwin Rd, Durham, NC 27705, USA; xi2.chen@duke.edu.

XC and SM contributed equally to this work.

Received: November 5, 2023

Accepted: March 11, 2024

Published: April 9, 2024

Citation: Chen X, Mangalesh S, He J, et al. Early single-examination optical coherence tomography biomarkers for treatment-requiring retinopathy of prematurity. *Invest Ophthalmol Vis Sci*. 2024;65(4):21. <https://doi.org/10.1167/iov.65.4.21>

PURPOSE. Optical coherence tomography (OCT) is an emerging adjunct imaging modality to evaluate retinopathy of prematurity (ROP). From an 11-year research database, we identify early OCT biomarkers that predict treatment-requiring ROP (TR-ROP).

METHODS. For preterm infants with acceptable OCT images at 32 ± 1 weeks postmenstrual age (PMA), we extracted the following measures: total retina, inner retinal layer (IRL), and outer retinal layer (ORL) thicknesses at the fovea and the parafovea, inner nuclear layer (INL) and choroidal thickness, parafovea/fovea (P/F) ratio, and presence of macular edema. Using univariable and multivariable logistic regression models, we evaluated the association between retinal and choroidal OCT measurements at 32 ± 1 weeks PMA and development of TR-ROP.

RESULTS. Of 277 eyes (145 infants) with usable OCT images, 67 eyes had TR-ROP. Lower P/F ratio ($P < 0.0001$), thicker foveal IRL ($P = 0.0001$), and thinner choroid ($P = 0.03$) were associated with TR-ROP in univariable analysis, but lost significance of association when adjusted for gestational age and race. Absence of macular edema was associated with TR-ROP when adjusted for gestational age and race ($P = 0.01$). In 185 eyes without macular edema, P/F ratio was associated with TR-ROP in both univariable analysis ($P < 0.0001$) and multivariable analysis ($P = 0.02$) with adjustment for gestational age and race.

CONCLUSIONS. Presence of macular edema at 32 ± 1 weeks PMA in infants with lower gestational age may be protective against TR-ROP. In infants without macular edema, P/F ratio may be an early OCT biomarker for development of TR-ROP. Incorporation of early OCT biomarkers may be useful in prediction of TR-ROP.

Keywords: optical coherence tomography (OCT), biomarkers, retinopathy of prematurity (ROP), macular edema, treatment-requiring ROP (TR-ROP)

Retinopathy of prematurity (ROP) is one of the leading causes of childhood blindness. ROP is caused by delayed retinal vascular development which may be followed by pathological neovascularization. Preterm infants usually undergo a series of ophthalmology examinations for ROP screening which are not only stressful but also require trained physicians to perform the examination.^{1,2} Although telemedicine platforms using wide-field retinal imaging by accredited non-physicians have been established to cope with the discrepancy between the increasing preterm infant population and the disproportionate number of trained specialists, the bright light from these cameras is still a potential source of infant stress.³⁻⁵ Efforts have been made to identify predictors for severe, treatment-requiring ROP (TR-ROP) for risk stratification and decrease the frequency of this examination.⁶⁻⁹

Over the past few years, portable, bedside optical coherence tomography (OCT) has become an emerging adjunct

imaging modality to evaluate ROP. Our group has shown that OCT imaging is less stressful than eye examinations using indirect ophthalmoscopy in preterm infants undergoing ROP screening.¹⁰ Studies using commercial and/or research portable OCT systems have increased our understanding of retinal development in preterm infants and been beneficial to evaluate the utility of OCT as a viable screening method for ROP,¹¹⁻¹⁷ or to assess the impact of advanced ROP.¹⁸ OCT-based vascular severity score and vitreous findings, as well as retinal and choroidal thicknesses at the fovea and the vascular-avascular junction, have been shown to associate with ROP severity.^{15,19-21} However, OCT findings associated with ROP to date have been evaluated typically in studies that pooled visits across the nursery period (e.g. 32–42 weeks PMA) or from visits at older ages in the nursery.²⁰⁻²⁸ What are lacking are early OCT findings that could be used to predict ROP disease activity prior to development of TR-ROP.

In this study, we aim to identify early OCT biomarkers predicting TR-ROP prior to ROP treatment. Because ROP leads to delayed retinal vascular development, we anticipate that identifying that delay in the macula early in the nursery will aid in prediction of TR-ROP. We and other groups have found that vascularized retina is thicker than avascular retina,^{29–31} and thus one premise is that a delay in macular vascularization will result in thinner parafoveal retinal thickness.^{31,32} We therefore hypothesize that early OCT findings, such as retinal and choroidal thicknesses or presence of macular edema at 32 ± 1 weeks postmenstrual age (PMA), can aid in the prediction of TR-ROP. These early OCT findings may serve as biomarkers for TR-ROP, and incorporation of these findings may improve enrollment and selection for ROP treatment trials and eventually for clinical care.

METHODS

Preterm Infant Retinal OCT Database

We have built an infant retinal OCT database from the prior studies conducted at our center between January 2009 and December 2020. For the current secondary analysis, we included data from four prior Duke Health institutional review board (IRB)-approved prospective studies that included inborn and outborn preterm infants: (1) spectral-domain OCT imaging of infant eyes study (Hartwell Foundation research grant; enrollment period January 15, 2009 to July 20, 2009); (2) OCT at the bedside study (a pilot Duke Clinical and Translational Science Project Award; enrollment period July 30, 2009 to March 25, 2016); (3) association of inflammatory markers and cystoid macular edema in very preterm infants study (Research to Prevent Blindness grant; enrollment period July 1, 2015 to December 21, 2015); and (4) BabySTEPS1 (R01EY025009; enrollment period August 12, 2016 to December 30, 2020). This study adheres to the tenets of the Declaration of Helsinki. Duke Health IRB determined the study satisfied relevant privacy rules and the Food and Drug Administration (FDA) regulations and was exempt from further review.

Imaging Session Selection

Images from a single OCT imaging session between 31 and 33 weeks PMA (32 ± 1 weeks PMA) in preterm infant eyes with documented eventual ROP treatment status were selected for this analysis. The PMA at imaging was calculated using the best estimate of gestational age extracted from medical records of the infant. The selection criteria were as follows:

1. We selected a single visit within the window of 32 ± 1 weeks PMA.
2. When multiple visits were available within this window, we used the visit closest to 32 weeks PMA.
3. When only visits at 31 and 33 weeks PMA were available, we used either the visit with better OCT image quality or chose the visit at random when the quality was comparable.
4. We used data from both eyes. In the scenario where data from one eye only was available at 32 weeks PMA, but data from both eyes were available at other visits, we used the visit at 32 weeks PMA.

OCT Image Analysis and Measures

The OCT data extracted were captured using three handheld OCT systems: Leica Envisu spectral-domain (SD) OCT and two investigational swept source (SS) OCT systems - ultracompact (UC) 2 (100 kHz) and UC3 (200 kHz). We have shown comparable repeatability and reproducibility of axial and lateral measurements between the SD OCT and the investigational SS OCT systems.³³ The best foveal volume from the imaging session was selected by experienced infant OCT grader and fovea was marked. Semi-automated segmentation of retinal layers to extract thickness measurements in the central foveal frame was performed using the proprietary infant-specific software DOCTRAP with manual correction by a trained OCT grader.²⁰ Retinal thicknesses were extracted using custom MATLAB codes at the foveal center and the parafovea. The OCT measures tested in this analysis include total retinal thickness at the fovea and the parafovea (average of point thicknesses on either side of the fovea at 1000 μm), inner retinal layer (IRL) thickness at the fovea and the parafovea (measured from the internal limiting membrane (ILM) to the boundary between the inner plexiform layer (IPL) and the inner nuclear layer (INL)), outer retinal layer (ORL) thickness at the fovea and the parafovea (measured from the boundary between the INL and outer plexiform layer (OPL) to the Bruch's membrane), parafovea/fovea ratio (P/F ratio, calculated by total retinal thickness at the parafovea over the total retinal thickness at the fovea), INL thickness (averaged over central 2000 μm), and choroidal thickness (averaged across the central 2000 μm). Presence of macular edema was defined as INL thickness above 71.25 μm based on our previous report.³⁴

Statistical Analysis

We performed all statistical analyses using SAS version 9.4 (SAS Institute Inc., Cary, NC, USA). We evaluated how each of the retinal and choroidal OCT measures at 32 ± 1 weeks PMA were associated with the development of TR-ROP using univariable logistic regression models followed by multivariable logistic regression models adjusted by gestational age and race (birth weight was not included due to its high collinearity with gestational age). The unadjusted and adjusted odds ratios (ORs) and its 95% confidence intervals (95% CIs) for each OCT measure were calculated. The performance of prediction of TR-ROP using OCT measures was evaluated using area under receiver operating characteristic (ROC) curve (AUC). We performed these analyses among all eyes and among eyes without macular edema to eliminate the possible confounding effect of macular edema. All these analyses were performed using the eye as the unit of analysis, and the inter-eye correlation was accounted for by using generalized estimating equations (GEEs).

RESULTS

This study included 277 eyes from 145 infants (48% females) with OCT images at 32 ± 1 weeks PMA, from the 2009 to 2021 database. Infant demographic information is described in Table 1. The mean (standard deviation) gestational age was 26.3 (2.1) weeks, and birth weight was 873.6 (257.6) grams. Sixty-seven (67) out of the 277 eyes (from 36 (24.8%) of 145 infants) received treatment

TABLE 1. Characteristics of Study Participants (*N* = 145 Infants)

Gestational age, wk	
Mean (SD)	26.33 (2.08)
PMA at OCT imaging, wk	
31	16 (11.0%)
32	77 (53.1%)
33	52 (35.9%)
Birth weight, g	
Mean (SD)	873.61 (257.62)
Gender	
F	69 (47.6%)
M	76 (52.4%)
Race	
Asian	2 (1.4%)
Black	70 (48.3%)
White	65 (44.8%)
More than one	8 (5.5%)
Max stage, 290 eyes	
0	75 (25.9%)
1	32 (11.0%)
2	111 (38.3%)
3	69 (23.8%)
4A	1 (0.3%)
Max plus, 290 eyes	
None	195 (67.2%)
Pre-plus	36 (12.4%)
Plus	59 (20.3%)
Treatment for type 1 ROP, 290 eyes	
No	220 (75.9%)
Yes	70 (24.1%)
Treatment for type 1 ROP	
No treatment	109 (75.2%)
One eye only	2 (1.4%)
Both eyes	34 (23.4%)

(laser photocoagulation, bevacizumab injection, or both) for type 1 ROP.

The descriptive analysis of retinal and choroidal OCT thickness measurements is listed in Table 2. There was high agreement between the left and right eye OCT thickness measurements, as shown in Supplementary Figure S1. Macular edema based on INL thickness was present in 75 eyes (43 infants) of 272 eyes (144 infants), with 5 eyes excluded due to incomplete measurements (Fig.). The correlations among OCT thickness measurements were not strong except for correlation between total retinal thickness and IRL thickness at the parafovea (Pearson correlation coefficient $\rho = 0.79$), P/F ratio and total retinal thickness at the fovea ($\rho = -0.77$), and averaged INL thickness and total retinal thickness at the fovea ($\rho = 0.91$; Supplementary Table S1). These strong correlations were expected due to the overlapping nature of these measurements.

Association of OCT Measures at 32 ± 1 Weeks PMA and TR-ROP Among All Eyes

In the univariable analysis, increased IRL thickness at the fovea (OR = 1.38, 95% CI = 1.17 to 1.62, $P = 0.0001$), decreased choroidal thickness (OR = 0.94, 95% CI = 0.89 to 0.995, $P = 0.03$), and lower P/F ratio (OR = 0.82, 95% CI = 0.75 to 0.89, $P < 0.0001$) were significantly associated with TR-ROP (Table 3). As expected, lower birth weight (OR = 0.96, 95% CI = 0.91 to 0.97, $P < 0.0001$) and lower gestational age (OR = 0.39, 95% CI = 0.25 to 0.60, $P < 0.0001$) were also significantly associated with TR-ROP (Table 3). The significance of association of the OCT parameters did not remain when adjusted for gestational age and race (see Table 3).

TABLE 2. Descriptive Analysis of Optical Coherence Tomography Thickness Measurements

	OD	OS	OD + OS	Non-TR (OD + OS)	TR (OD + OS)
IRL thickness at fovea, μm					
<i>N</i>	140	137	277	210	67
Mean (SD)	55.90 (22.43)	53.51 (22.60)	54.72 (22.51)	50.78 (20.47)	67.05 (24.24)
IRL thickness at parafovea, μm					
<i>N</i>	133	130	263	200	63
Mean (SD)	112.75 (23.10)	111.81 (22.21)	112.28 (22.62)	114.02 (20.33)	106.76 (28.20)
ORL thickness at fovea, μm					
<i>N</i>	140	132	272	206	66
Mean (SD)	50.90 (15.79)	49.75 (14.87)	50.34 (15.33)	49.59 (15.67)	52.70 (14.07)
ORL thickness at parafovea, μm					
<i>N</i>	133	125	258	196	62
Mean (SD)	53.14 (11.40)	52.74 (10.99)	52.94 (11.19)	53.05 (10.59)	52.62 (12.98)
Thickness total retina-RPE at fovea, μm					
<i>N</i>	140	137	277	210	67
Mean (SD)	180.79 (80.17)	178.87 (77.92)	179.84 (78.93)	176.20 (83.61)	191.26 (61.16)
Total retina thickness at parafovea, μm					
<i>N</i>	132	130	262	199	63
Mean (SD)	228.35 (41.04)	227.17 (42.10)	227.77 (41.49)	230.56 (38.38)	218.95 (49.39)
Thickness INL averaged 2000 μm across fovea, μm					
<i>N</i>	140	132	272	206	66
Mean (SD)	71.03 (40.97)	70.04 (36.94)	70.55 (39.00)	71.65 (39.92)	67.11 (36.01)
Thickness choroid averaged 2000 μm across fovea, μm					
<i>N</i>	136	132	268	202	66
Mean (SD)	202.04 (72.28)	203.10 (77.69)	202.56 (74.85)	210.28 (75.38)	178.95 (68.49)
P/F ratio					
<i>N</i>	132	130	262	199	63
Mean (SD)	1.42 (0.44)	1.41 (0.42)	1.41 (0.43)	1.49 (0.46)	1.18 (0.21)

IRL, inner retinal layer; INL, inner nuclear layer; ORL, outer retinal layer; P/F ratio, parafovea/fovea ratio; SD, standard deviation.

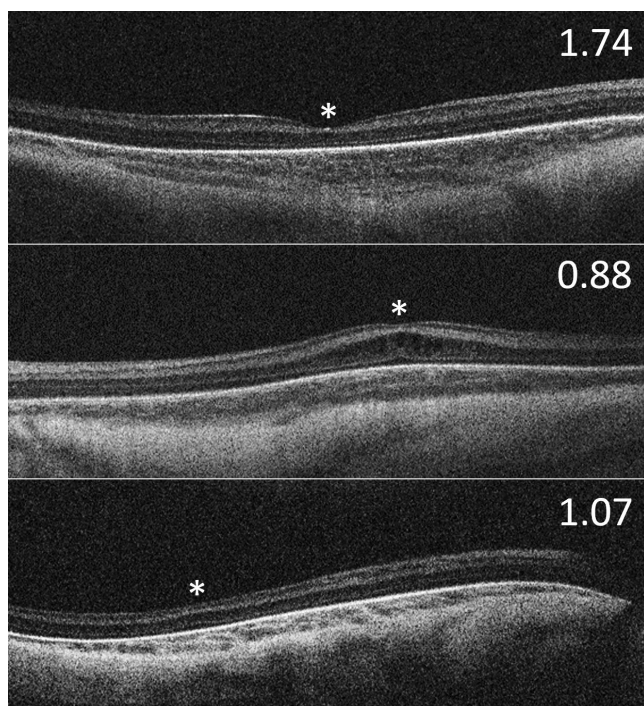


FIGURE. Representative foveal optical coherence tomography scans of infants at 32 ± 1 weeks postmenstrual age with their respective parafoveal/foveal (P/F) ratio. *Top panel:* Foveal scan from an infant without macular edema who did not develop treatment-requiring retinopathy of prematurity (TR-ROP). *Middle panel:* Foveal scan from an infant with macular edema who did not develop TR-ROP. *Bottom panel:* Foveal scan from an infant without macular edema who developed TR-ROP with a low P/F ratio. The asterisks mark the location of the fovea. P/F ratio is calculated as the ratio between the average parafoveal retinal thickness at $1000 \mu\text{m}$ nasal and temporal to the fovea divided by the central foveal thickness. The corresponding P/F ratio is shown in the *top right corner of the image*. Note that the presence of macular edema confounds the P/F ratio (*middle panel*).

Association of Macular Edema and TR-ROP Among All Eyes

We assessed the association between the presence of macular edema at 32 ± 1 weeks PMA with development of TR-ROP in 272 eyes. In univariable analysis, the absence of macular edema was not significantly associated with TR-ROP (OR = 0.69, 95% CI = 0.29 to 1.64, $P = 0.40$; see Table 3). However, when adjusted for gestational age and race, the absence of macular edema became significantly associated with TR-ROP (OR = 0.21, 95% CI = 0.06 to 0.70, $P = 0.01$; see Table 3). This appeared to be due to the increased prevalence of early macular edema in infants with lower gestational age (Supplementary Table S2). The multivariable model that included gestational age, race, and macular edema had an AUC of 0.91 (95% CI = 0.88 to 0.94) for predicting TR-ROP, which was not significantly higher than that from the model with gestational age and race (AUC = 0.89, 95% CI = 0.86 to 0.92).

Association of OCT Measures at 32 ± 1 Weeks PMA and TR-ROP Among Eyes Without Macular Edema

To eliminate the possible confounding effect of macular edema on the association of OCT thickness and TR-ROP,

we analyzed a subset that excluded 75 eyes with macular edema. In univariable analysis of the 197 eyes without macular edema, increased IRL thickness at the fovea (OR = 1.42, 95% CI = 1.16 to 1.75, $P = 0.0007$), increased ORL thickness at the fovea (OR = 1.49, 95% CI = 1.07 to 2.06, $P = 0.02$), increased total retinal thickness at the fovea (OR = 1.40, 95% CI = 1.22 to 1.60, $P < 0.0001$), decreased IRL thickness at the parafovea (OR = 0.70, 95% CI = 0.56 to 0.88, $P = 0.003$), decreased total retinal thickness at the parafovea (OR = 0.85, 95% CI = 0.74 to 0.98, $P = 0.03$), decreased choroidal thickness (OR = 0.93, 95% CI = 0.87 to 0.99, $P = 0.03$), and lower P/F ratio (OR = 0.59, 95% CI = 0.49 to 0.71, $P < 0.0001$) were significantly associated with TR-ROP (Table 4). When adjusted for gestational age and race, lower P/F ratio remained significantly associated with TR-ROP (OR = 0.74, 95% CI = 0.59 to 0.93, $P = 0.02$; see Table 4).

The multivariable model that included gestational age and P/F ratio as predictors yielded AUC = 0.91 (95% CI = 0.87 to 0.95), which was higher than the AUC from gestational age alone (AUC = 0.89, 95% CI = 0.84 to 0.93, $P = 0.08$), or birth weight alone (AUC = 0.83, 95% CI = 0.76 to 0.86, $P = 0.002$), and similar to the AUC from model with gestational age and race (AUC = 0.92, 95% CI = 0.88 to 0.95, $P = 0.94$).

DISCUSSION

We utilized the largest early preterm infant (32 ± 1 weeks PMA) retinal OCT database reported to date to investigate early OCT biomarkers for TR-ROP. An advantage of this database was that it included a high proportion of eyes that later required ROP treatment (67 (24%) of 277 eyes). Whereas retinal and choroidal thicknesses in these early preterm infants were associated with TR-ROP, the impact of gestational age and race outweighed most measures as predictors. Early-onset macular edema in the youngest infants appeared to be a protective biomarker against the development of TR-ROP. In contrast, in infants without macular edema, lower P/F ratio, a marker of an underdeveloped fovea, appeared to be a biomarker predicting TR-ROP.

Identifying biomarkers predicting TR-ROP on bedside OCT imaging is an attractive aspect of neonatal research due to OCT's noninvasive and reproducible nature to measure retinal layer thickness in the infant eye.^{33,35} However, in our current study, the significant impact of gestational age and race outweighed most candidate OCT biomarkers. This may be due to the known inter-relationship between gestational age and retinal thicknesses in preterm infants, particularly the IRL.²⁶ From the 102 infants in BabySTEPS, we reported that thicker IRL at the foveal center was highly correlated with gestational age from as early as 30 weeks PMA and the process of foveation is likely arrested at preterm birth.²⁶ Our other candidate, thin choroid, was previously shown to be associated with more severe ROP,²⁰ however, the predictive power of choroidal thickness was also outweighed by the effect of gestational age and race. In addition, we did not find a significant relationship between gender and development of TR-ROP in our dataset.

We found that early onset macular edema at 32 ± 1 weeks PMA appears protective against development of TR-ROP. Infant macular edema is a unique but common finding of the preterm retina. It is estimated to occur in 30% to 60% of preterm infant eyes,^{23,25,27,28,36–38} and may assume different morphology depending on the timing of onset.^{20,39} The etiology of macular edema is still unclear, and hypotheses

TABLE 3. Univariable and Multivariable Analysis for the Association of OCT Measures at 32 ± 1 Weeks Postmenstrual Age and Development Treatment-Requiring Retinopathy of Prematurity in all Eyes

OCT Features/Demographics	# of Eyes	# of Eyes With Treatment	Unadjusted OR (95% CI)	P Value	GA and Race Adjusted OR (95% CI)	P Value
Thickness at fovea, μ (OR for per 10 μ m increase)						
IRL	277	67 (24.2%)	1.38 (1.17, 1.62)	0.0001	1.11 (0.92, 1.35)	0.28
ORL	272	66 (24.3%)	1.13 (0.92, 1.40)	0.24	1.02 (0.76, 1.36)	0.91
Total retina-RPE	277	67 (24.2%)	1.02 (0.98, 1.06)	0.26	0.96 (0.90, 1.02)	0.18
Thickness at parafovea, μ m (OR for per 10 μ m increase)						
IRL	263	63 (24.0%)	0.86 (0.70, 1.06)	0.16	1.02 (0.84, 1.23)	0.88
ORL	258	62 (24.0%)	0.97 (0.67, 1.39)	0.85	1.18 (0.81, 1.73)	0.39
Total retina	262	63 (24.0%)	0.93 (0.83, 1.05)	0.21	0.96 (0.85, 1.07)	0.46
INL	272	66 (24.3%)	0.97 (0.86, 1.09)	0.58	0.88 (0.74, 1.06)	0.18
Choroid	268	66 (24.6%)	0.94 (0.89, 0.995)	0.03	1.01 (0.95, 1.09)	0.71
P/F ratio (per 0.1 increase)	262	63 (24.0%)	0.82 (0.75, 0.89)	<0.0001	1.01 (0.87, 1.17)	0.88
Birth weight, per 10 g increase	277	67 (24.2%)	0.94 (0.91, 0.97)	<0.0001	1.002 (0.97, 1.04)	0.93
Gestational age, per week increase	277	67 (24.2%)	0.39 (0.25, 0.60)	<0.0001		
Gender				0.99		0.87
F	132	32 (24.2%)	Reference		Reference	
M	145	35 (24.1%)	0.99 (0.46, 2.14)		1.08 (0.44, 2.64)	
Race				0.06		
White	122	32 (26.2%)	Reference			
Black	135	23 (17.0%)	0.58 (0.25, 1.34)	0.20		
Other	20	12 (60%)	4.22 (1.06, 16.84)	0.04		
Macular edema				0.40		0.01
No	197	51 (25.9%)	Reference		Reference	
Yes	75	15 (20.0%)	0.69 (0.29, 1.64)		0.21 (0.06, 0.70)	

INL, inner nuclear layer; IRL, inner retinal layers; OR, odds ratio (for treated ROP); ORL, outer retinal layers; P/F ratio, parafovea/fovea ratio. Variables with *P* value < 0.10 were selected to enter the initial multivariable analysis.

include vascular leakage, retrograde cell death, and others. Although some studies showed that macular edema may be associated with worse visual acuity and neurodevelopmental outcomes,^{40,41} in the recent BabySTEPS, our group did not find an association with worse visual acuity.⁴² We

have previously reported the biphasic presence of macular edema in preterm infants in an analysis that included infants from groups 1 to 3 of this study (see the Methods section).³⁹ Macular edema occurring at 32 ± 1 weeks PMA, considered as early-onset edema, was more severe when compared to

TABLE 4. Univariable and Multivariable Analysis of the Association of OCT Measures at 32 ± 1 Weeks PMA With Treatment-Requiring ROP in Eyes Without Macular Edema

OCT Features/Demographics	# of Eyes Total	# of Eyes With Treatment	Unadjusted OR (95% CI)	P Value	GA and Race Adjusted OR (95% CI)	P Value
Thickness at fovea, μ m (OR is for per 10 μ m increase)						
IRL	197	51 (25.9%)	1.42 (1.16, 1.75)	0.0007	1.05 (0.82, 1.35)	0.70
ORL	197	51 (25.9%)	1.49 (1.07, 2.06)	0.02	1.36 (0.96, 1.92)	0.08
Total retina-RPE	197	51 (25.9%)	1.40 (1.22, 1.60)	<0.0001	1.15 (0.99, 1.35)	0.08
Average thickness at parafovea, μ m (OR is for per 10 μ m increase)						
IRL	185	48 (25.9%)	0.70 (0.56, 0.88)	0.003	0.79 (0.58, 1.07)	0.12
ORL	185	48 (25.9%)	0.91 (0.56, 1.48)	0.71	1.35 (0.78, 2.35)	0.28
Total retina	185	48 (25.9%)	0.85 (0.74, 0.98)	0.03	0.96 (0.79, 1.17)	0.70
INL	197	51 (25.9%)	1.58 (0.90, 2.80)	0.11	1.35 (0.71, 2.59)	0.36
Choroid	190	51 (26.8%)	0.93 (0.87, 0.99)	0.03	1.01 (0.94, 1.09)	0.74
P/F ratio, per 0.1 increase	185	48 (25.9%)	0.59 (0.49, 0.71)	<0.0001	0.74 (0.59, 0.93)	0.02
Birth weight, per 10 g increase	197	51 (25.9%)	0.94 (0.91, 0.97)	0.0001	1.02 (0.98, 1.07)	0.29
Gestational age, per week increase	197	51 (25.9%)	0.37 (0.23, 0.59)	<0.0001		
Gender				0.46		0.17
F	97	22 (22.7%)	Reference		Reference	
M	100	29 (29%)	1.39 (0.58, 3.34)		2.24 (0.71, 7.07)	
Race				0.14		
White	82	24 (29.3%)	Reference			
Black	98	18 (18.4%)	0.54 (0.21, 1.41)	0.21		
Other	17	9 (52.9%)	2.72 (0.62, 11.93)	0.19		

INL, inner nuclear layer; IRL, inner retinal layer; OR, odds ratio (for treated ROP); ORL, outer retinal layer; P/F ratio: parafovea/fovea ratio. Variables with *P* value < 0.10 were selected to enter the initial multivariable analysis.

macular edema that occurred after 35 weeks PMA.³⁹ In our current study, although we did not include the severity of edema in this analysis, we found a protective effect of early-onset macular edema against development of TR-ROP. We hypothesize that early-onset macular edema is indicative of a more mature state of retinal vascular development. However, this hypothesis will need to be tested with direct imaging of the status of vascularization in these eyes.

We believed that macular edema complicates analysis of the P/F ratio by increasing the central foveal thickness and therefore lowering the P/F ratio, and that excluding eyes with edema allowed a subgroup analysis without this confounding factor. In eyes without macular edema, despite the substantial impact of gestational age, a lower P/F ratio was found to be significantly associated with future development of TR-ROP. Perifoveal vascularization has been shown to associate with inner retinal thickening at the parafovea and establishment of the foveal pit.³¹ Therefore, we hypothesize that perifoveal vascularization leads to increased retinal thickness at the parafovea and a higher P/F ratio. The lower P/F ratio is indicative of a flat or indeterminate fovea at 32 ± 1 weeks PMA and appears to be a biomarker of immature foveal development, resulting from a simultaneous lag in both neural and vascular development in the preterm infant retina. Thus, in a large database in preterm infants at an early age, although the “arrested” fovea is strongly associated with lower gestational age, it is also indicative of poorer retinal vascular development beyond gestational age and race. Whether this finding is due to vascular endothelial growth factor overdrive found in eyes that later develop severe ROP affecting human foveal development remains unclear.

Preterm infants have multiple sequential ROP examinations while in the nursery. The purpose of these repeated examinations is to identify eyes progressing to TR-ROP. However, these examinations are associated with discomfort and stress that may have long-term neurodevelopmental consequences.^{43–45} Therefore, efforts have been made to create prediction models to identify eyes that are more likely to develop TR-ROP in an effort to decrease the frequency of screening. Previous studies have identified the vascular severity score at 32 ± 1 weeks PMA and vascular development as potential biomarkers that may enhance the prediction of severe ROP.^{9,46} In the current study, we found that in infants with lower gestational age, the presence of early macular edema appeared protective against development of TR-ROP. Additionally, despite the overwhelming effect of gestational age and race on many potential early retinal and choroidal OCT biomarkers predicting TR-ROP, a lower P/F ratio in eyes without macular edema appeared as an attractive potential candidate that could be utilized in the prediction of TR-ROP and in risk stratification for future clinical trials. Thus, in an ongoing clinical study (BabySTEPS2: NCT04995341), in addition to the vascular severity score, we plan to validate OCT biomarkers, such as the presence of early-onset macular edema and lower P/F ratio to predict future TR-ROP.

Acknowledgments

Supported by funding from the NIH R21EY034138 (Ying and Toth), R01EY025009 (Toth) The Hartwell Foundation (Toth), Research to Prevent Blindness (Toth and Chen), R01EY034134 (Chen), and P30EY005722 (Duke Core). The funding agencies did not participate in design, data collection, or interpretation of the study.

Disclosure: **X. Chen**, None; **S. Mangalesh**, None; **J. He**, None; **K.P. Winter**, None; **V. Tai**, None; **C.A. Toth**, reports royalties from Alcon for surgical technologies licensed through Duke University, patents pending related to OCT technologies, and equity ownership of Theia Imaging; **G.-S. Ying**, None

References

1. Binenbaum G, Bell EF, Donohue P, et al. Development of modified screening criteria for retinopathy of prematurity: primary results from the postnatal growth and retinopathy of prematurity study. *JAMA Ophthalmol*. 2018;136(9):1034–1040.
2. Rush R, Rush S, Ighani F, Anderson B, Irwin M, Naqvi M. The effects of comfort care on the pain response in preterm infants undergoing screening for retinopathy of prematurity. *Retina (Philadelphia, Pa)*. 2005;25(1):59–62.
3. Fierson WM, Capone A, Jr. Telemedicine for evaluation of retinopathy of prematurity. *Pediatrics*. 2015;135(1):e238–e254.
4. Vinekar A, Rao SV, Murthy S, et al. A novel, low-cost, wide-field, infant retinal camera, “neo”: technical and safety report for the use on premature infants. *Transl Vis Sci Technol*. 2019;8(2):2.
5. Wade KC, Pistilli M, Baumritter A, et al. Safety of retinopathy of prematurity examination and imaging in premature infants. *J Pediatr*. 2015;167(5):994–1000.e2.
6. Ying GS. A prediction model for retinopathy of prematurity – is it ready for prime time? *JAMA Ophthalmol*. 2020;138(1):29–30.
7. Iu LPL, Yip WWK, Lok JYC, et al. Prediction model to predict type 1 retinopathy of prematurity using gestational age and birth weight (PW-ROP). *Br J Ophthalmol*. 2023;107(7):1007–1011.
8. Shah S, Slaney E, VerHage E, et al. Application of artificial intelligence in the early detection of retinopathy of prematurity: review of the literature. *Neonatology*. 2023;1–8.
9. Coyner AS, Chen JS, Singh P, et al. Single-examination risk prediction of severe retinopathy of prematurity. *Pediatrics*. 2021;148(6):e2021051772.
10. Mangalesh S, Sarin N, McGeehan B, et al. Preterm infant stress during handheld optical coherence tomography vs binocular indirect ophthalmoscopy examination for retinopathy of prematurity. *JAMA Ophthalmol*. 2021;139(5):567–574.
11. Maldonado RS, Izatt JA, Sarin N, et al. Optimizing hand-held spectral domain optical coherence tomography imaging for neonates, infants, and children. *Invest Ophthalmol Vis Sci*. 2010;51(5):2678–2685.
12. Nguyen TP, Ni S, Liang G, et al. Widefield optical coherence tomography in pediatric retina: a case series of intraoperative applications using a prototype handheld device. *Front Med*. 2022;9:860371.
13. Chen X, Mangalesh S, Dandridge A, et al. Spectral-domain OCT findings of retinal vascular-avascular junction in infants with retinopathy of prematurity. *Ophthalmol Retina*. 2018;2(9):963–971.
14. Mangalesh S, Seely KR, Tran-Viet D, et al. Integrated visualization highlighting retinal changes in retinopathy of prematurity from 3-dimensional optical coherence tomography data. *JAMA Ophthalmol*. 2022;140(7):725–729.
15. Nguyen TP, Ni S, Ostmo S, et al. Association of optical coherence tomography-measured fibrovascular ridge thickness and clinical disease stage in retinopathy of prematurity. *JAMA Ophthalmol*. 2022;140(11):1121–1127.
16. Kubsad D, Ohan MA, Wu JG, Cabrera MT. Vitreoretinal biomarkers of retinopathy of prematurity using handheld optical coherence tomography: a review. *Front Pediatr*. 2023;11:1191174.

17. Maldonado RS, O'Connell RV, Sarin N, et al. Dynamics of human foveal development after premature birth. *Ophthalmology*. 2011;118(12):2315–2325.
18. Chen X, Prakalapakorn SG, Freedman SF, Vajzovic L, Toth CA. Differentiating retinal detachment and retinoschisis using handheld optical coherence tomography in stage 4 retinopathy of prematurity. *JAMA Ophthalmol*. 2020;138(1):81–85.
19. Maldonado RS, Yuan E, Tran-Viet D, et al. Three-dimensional assessment of vascular and perivascular characteristics in subjects with retinopathy of prematurity. *Ophthalmology*. 2014;121(6):1289–1296.
20. Mangalesh S, McGeehan B, Tai V, et al. Macular OCT characteristics at 36 weeks' postmenstrual age in infants examined for retinopathy of prematurity. *Ophthalmol Retina*. 2021;5(6):580–592.
21. Legocki AT, Zepeda EM, Gillette TB, et al. Vitreous findings by handheld spectral-domain OCT correlate with retinopathy of prematurity severity. *Ophthalmol Retina*. 2020;4(10):1008–1015.
22. Zepeda EM, Shariff A, Gillette TB, et al. Vitreous bands identified by handheld spectral-domain optical coherence tomography among premature infants. *JAMA Ophthalmol*. 2018;136(7):753–758.
23. Dubis AM, Subramaniam CD, Godara P, Carroll J, Costakos DM. Subclinical macular findings in infants screened for retinopathy of prematurity with spectral-domain optical coherence tomography. *Ophthalmology*. 2013;120(8):1665–1671.
24. Erol MK, Coban DT, Ozdemir O, Dogan B, Tunay ZO, Bulut M. Choroidal thickness in infants with retinopathy of prematurity. *Retina (Philadelphia, Pa)*. 2016;36(6):1191–1198.
25. Maldonado RS, O'Connell R, Ascher SB, et al. Spectral-domain optical coherence tomographic assessment of severity of cystoid macular edema in retinopathy of prematurity. *Arch Ophthalmol (Chicago, Ill: 1960)*. 2012;130(5):569–578.
26. O'Sullivan ML, Ying GS, Mangalesh S, et al. Foveal differentiation and inner retinal displacement are arrested in extremely premature infants. *Invest Ophthalmol Vis Sci*. 2021;62(2):25.
27. Vinekar A, Avadhani K, Sivakumar M, et al. Understanding clinically undetected macular changes in early retinopathy of prematurity on spectral domain optical coherence tomography. *Invest Ophthalmol Vis Sci*. 2011;52(8):5183–5188.
28. Erol MK, Ozdemir O, Coban DT, et al. Macular findings obtained by spectral domain optical coherence tomography in retinopathy of prematurity. *J Ophthalmol*. 2014;2014:468653.
29. Buttery RG, Hinrichsen CF, Weller WL, Haight JR. How thick should a retina be? A comparative study of mammalian species with and without intraretinal vasculature. *Vision Res*. 1991;31(2):169–187.
30. Chase J. The evolution of retinal vascularization in mammals. A comparison of vascular and avascular retinæ. *Ophthalmology*. 1982;89(12):1518–1525.
31. Chen X, Viehland C, Tran-Viet D, et al. Capturing macular vascular development in an infant with retinopathy of prematurity. *JAMA Ophthalmol*. 2019;137(9):1083–1086.
32. Chen X, Imperio R, Seely KR, et al. Slow progressive perifoveal vascular formation in an infant with aggressive posterior retinopathy of prematurity. *Journal of AAPOS*. 2020;24(5):323–326.
33. Chen X, Tai V, McGeehan B, et al. Repeatability and reproducibility of axial and lateral measurements on handheld optical coherence tomography systems compared with tabletop system. *Transl Vis Sci Technol*. 2020;9(11):25.
34. O'Sullivan ML, Ying GS, Mangalesh S, et al. Foveal differentiation and inner retinal displacement are arrested in extremely premature infants. *Invest Ophthalmol Vis Sci*. 2021;62(2):25.
35. Wang KL, Chen X, Stinnett S, et al. Understanding the variability of handheld spectral-domain optical coherence tomography measurements in supine infants. *PLoS One*. 2019;14(12):e0225960.
36. Vinekar A, Avadhani K, Sivakumar M, et al. Macular edema in premature infants. *Ophthalmology*. 2012;119(6):1288–9.e1; author reply 1289–90.e1.
37. Vinekar A, Mangalesh S, Jayadev C, et al. Macular edema in Asian Indian premature infants with retinopathy of prematurity: impact on visual acuity and refractive status after 1-year. *Indian J Ophthalmol*. 2015;63(5):432–437.
38. Anwar S, Nath M, Gottlob I, Proudlock FA. Severity of cystoid macular oedema in preterm infants observed using hand-held spectral domain optical coherence tomography improves weekly with postmenstrual age. *Eye (Lond)*. 2023;37:3009–3014.
39. Mangalesh S, Wong BM, Chen X, et al. Morphological characteristics of early- versus late-onset macular edema in preterm infants. *J AAPOS*. 2020;24(5):303–306.
40. Rothman AL, Sevilla MB, Mangalesh S, et al. Thinner retinal nerve fiber layer in very preterm versus term infants and relationship to brain anatomy and neurodevelopment. *Am J Ophthalmol*. 2015;160(6):1296–1308.e2.
41. Rothman AL, Tran-Viet D, Gustafson KE, et al. Poorer neurodevelopmental outcomes associated with cystoid macular edema identified in preterm infants in the intensive care nursery. *Ophthalmology*. 2015;122(3):610–619.
42. Seely KR, Mangalesh S, Shen LL, et al. Association between retinal microanatomy in preterm infants and 9-month visual acuity. *JAMA Ophthalmol*. 2022;140(7):699–706.
43. Nist MD, Harrison TM, Steward DK. The biological embedding of neonatal stress exposure: a conceptual model describing the mechanisms of stress-induced neurodevelopmental impairment in preterm infants. *Res Nurs Health*. 2019;42(1):61–71.
44. Smith GC, Gutovich J, Smyser C, et al. Neonatal intensive care unit stress is associated with brain development in preterm infants. *Ann Neurol*. 2011;70(4):541–549.
45. Duerden EG, Grunau RE, Guo T, et al. Early procedural pain is associated with regionally-specific alterations in thalamic development in preterm neonates. *J Neurosci*. 2018;38(4):878–886.
46. Jang JH, Kim YC. Retinal vascular development in an immature retina at 33–34 weeks postmenstrual age predicts retinopathy of prematurity. *Sci Rep*. 2020;10(1):18111.