tvst

Article

Characteristics of Corneal Higher-Order Aberrations in Congenital Ectopia Lentis Patients

Huiwen Ye[1,*], Zhenzhen Liu[1,*], Qianzhong Cao[1], Charlotte Aimee Young[2], Zhangkai Lian[1], Xinyu Zhang[1], Danying Zheng[1], and Guangming Jin[1]

[1] State Key Laboratory of Ophthalmology, Zhongshan Ophthalmic Center, Sun Yat-sen University, Guangzhou, China
[2] Nanchang Eye Hospital, Third Affiliated Hospital of Nanchang University, Nanchang, China

Correspondence: Guangming Jin, State Key Laboratory of Ophthalmology, Zhongshan Ophthalmic Center, Sun Yat-sen University, Guangzhou 510000, China.
e-mail: jingm@mail2.sysu.edu.cn
Danying Zheng, State Key Laboratory of Ophthalmology, Zhongshan Ophthalmic Center, Sun Yat-sen University, Guangzhou 510000, China.
e-mail: zhengdyy@163.com

Received: June 2, 2021
Accepted: July 26, 2021
Published: August 20, 2021

Keywords: higher-order aberrations, congenital ectopia lentis; primary spherical aberrations

Citation: Ye H, Liu Z, Cao Q, Young CA, Lian Z, Zhang X, Zheng D, Jin G. Characteristics of corneal higher-order aberrations in congenital ectopia lentis patients. Transl Vis Sci Technol. 2021;10(9):24, https://doi.org/10.1167/tvst.10.9.24

Purpose: The purpose of this study was to investigate the characteristics of corneal higher-order aberrations (HOAs) in patients with congenital ectopia lentis (CEL).

Methods: Clinical characteristics and HOAs of 60 patients with CEL and 75 healthy controls at Zhongshan Ophthalmic Center in China were retrospectively analyzed. The Q value and the corneal HOAs in the CEL group and the controls were measured by using Pentacam and compared value between the CEL and control groups. The correlation between HOAs and age was investigated using the Pearson correlation analysis.

Results: The Q value of anterior corneal surface in the CEL group was larger than that in the controls (-0.41 ± 0.17 vs. -0.32 ± 0.13, $P = 0.001$); the total corneal horizontal coma in the CEL group were larger than that in the controls (0.24 ± 0.18 vs. -0.05 ± 0.14, $P < 0.001$); both the primary spherical aberrations of the anterior and total corneal surface were lower in the CEL group than that in the controls (for anterior corneal surface: 0.15 ± 0.08 vs. 0.27 ± 0.08 µm, $P < 0.001$; for total corneal surface: 0.10 ± 0.09 vs. 0.23 ± 0.09 µm, $P < 0.001$), the anterior and total corneal horizontal coma were negatively associated with age, whereas the anterior and total corneal spherical aberrations were positively associated with age in patients with CEL.

Conclusions: Patients with CEL had higher corneal horizontal coma and lower corneal vertical coma primary spherical aberrations than healthy controls.

Translational Relevance: These findings are informative for the clinical managements in patients with CEL.

Introduction

Congenital ectopia lentis (CEL) is characterized by displacement of the lens from its normal position due to abnormal development of zonular fibers, which can lead to severe refractive errors, astigmatism, and amblyopia.[1] CEL is often associated with systemic diseases, such as Marfan's syndrome, sulfite oxidase deficiency, and Weill-Marchesani syndrome. However, CEL can occur as an isolated ocular anomaly, and it is often accompanied by other ocular dysplasia. Petra Gehle has noted that quite a few patients with CEL have ocular features, such as flattened corneas, megalocornea, and even keratoconus, which may be associated with corneal dysplasia.[2] Besides, the morphology of corneal in CEL is markedly different from that of normal subjects in our clinical practice, which suggest that the corneal characteristics of patients with CEL are special and may be different from those of the healthy population.

Considering the cornea accounts for about 70% of the refractive power of the eye,[3] it is worth noting that corneal higher-order aberrations (HOAs; also a major

Copyright 2021 The Authors

This work is licensed under a Creative Commons Attribution-NonCommercial-NoDerivatives 4.0 International License.

Downloaded from abstracts.iovs.org on 04/25/2024

translational vision science & technology

contributor to ocular aberrations) could significantly affect optimal vision quality.[4] The characterization of corneal HOAs is important in assessing the patients' visual function and recent studies elucidated the importance of corneal HOAs in various kinds of corneal diseases, such as herpetic keratitis, bullous keratopathy, perforation, Stevens-Johnson syndrome, and infectious keratitis.[5–7] However, the corneal HOAs in CEL is still poorly understood. The purpose of this study is to characterize corneal HOAs in CEL and to evaluate the correlation with visual function of the patients with CEL.

In this study, we aim to investigate the characteristics and distribution of corneal HOAs in eyes of patients with CEL.

Patients and Methods

Design

This retrospective study was conducted at the ZhongShan Ophthalmic Center, Sun Yet-Sun University, Guangzhou, China. All participants had signed an informed consent form. The study was approved by the Human Research Ethics Committee of ZhongShan Ophthalmic Center and followed the principles of the Declaration of Helsinki, and the institutional review board (IRB) was 2020KYPJ146.

Patients

The study reviewed the medical records of patients with CEL treated between July 2014 and June 2020. The included criteria were as follows: (1) patients diagnosed with bilateral ectopia lentis (EL); and (2) patients younger than 45 years old. The exclusion criteria were as follow: (1) patients with secondary lens dislocations or lens dislocation caused by ocular trauma were excluded; (2) patients with ocular surgery history; and (3) patients with pre-existing corneal diseases or wear contact lenses that may influence corneal higher-order aberrations.

Corneal Assessment

We used the rotating Scheimpflug camera with the Pentacam HR system (Oculus Inc., Wetzlar, Germany) to measure the anterior, posterior, and total higher-order corneal aberrations. All measurements were performed by the same experienced technician. The measurements were performed using the 6.00 mm pupil scan diameter. Corneal parameters included Q value, horizontal coma Z (3, 1), vertical coma Z (3, −1), oblique trefoil Z (3, 3), vertical trefoil Z (3, −3), and primary spherical aberration Z (4, 0) of the anterior corneal surface, posterior corneal, and total corneal surface were obtained. Basic information from the medical records were also included.

Statistical Analysis

The normality of the distributions of continuous data was assessed by Kolmogorov–Smirnov test and all continuous data with normal distribution are presented as mean ± standard deviations (SDs). All variables were statistically analyzed for quantitative data. The student's test and Pearson's χ^2 test were used to compare the differences between the CEL and control group; Pearson correlation analysis was used to evaluate the correlation between HOAs and age. All data was analyzed with SPSS version 22.0 (SPSS/IBM Inc, Chicago, IL, USA). The P values less than 0.05 were considered statistically significant.

Results

Demographic Characteristics of Included Subjects

This retrospective case-control study included 135 eyes from 135 subjects who underwent measurements using the rotating Scheimpflug camera (Pentacam). The demographic characteristics and clinical features of 60 patients with CEL and 75 healthy control eyes are shown in Table 1. The average age of the two groups was13.1 ± 8.47 and15.3 ± 7.18, respectively ($P = 0.103$).

Characteristics of Corneal Pattern of Patients With CEL

Figure 1 shows the pentacam-4 refractive maps for a healthy control and a patient with CEL. Compared with healthy subjects, the anterior surface sagittal map of patients with CEL showed non-collar-like symmetry and an abnormal irregular height map, whereas the anterior surface sagittal map of normal controls showed a tie-like symmetric distribution and a symmetric hourglass shape in the height map.

As Table 2 shows, there is a statistically significant difference in the Q value (a key corneal parameter that reflects the corneal shape) of the anterior surface between the CEL group and controls (−0.41 ± 0.17 for the CEL group versus −0.32 ± 0.13 for the controls, $P = 0.001$).

translational vision science & technology

Downloaded from abstracts.iovs.org on 04/25/2024

Table 1. The Demographic and Clinical Features of 60 Patients With CEL at Baseline.

	Overall	CEL Group	Control Group	*P* Value
Patients (*n*)	135	60	75	–
Male/female (*n*)	70/65	32/28	38/37	0.320
Mean age (SD, range)	14.34 ± 7.82	13.11 ± 8.47	15.32 ± 7.18	0.103
Age group (*n*)				
≤10 years	49	30	19	0.803
10–20 years	53	15	38	0.522
>20 years	33	15	18	0.908

SD, standard deviation.

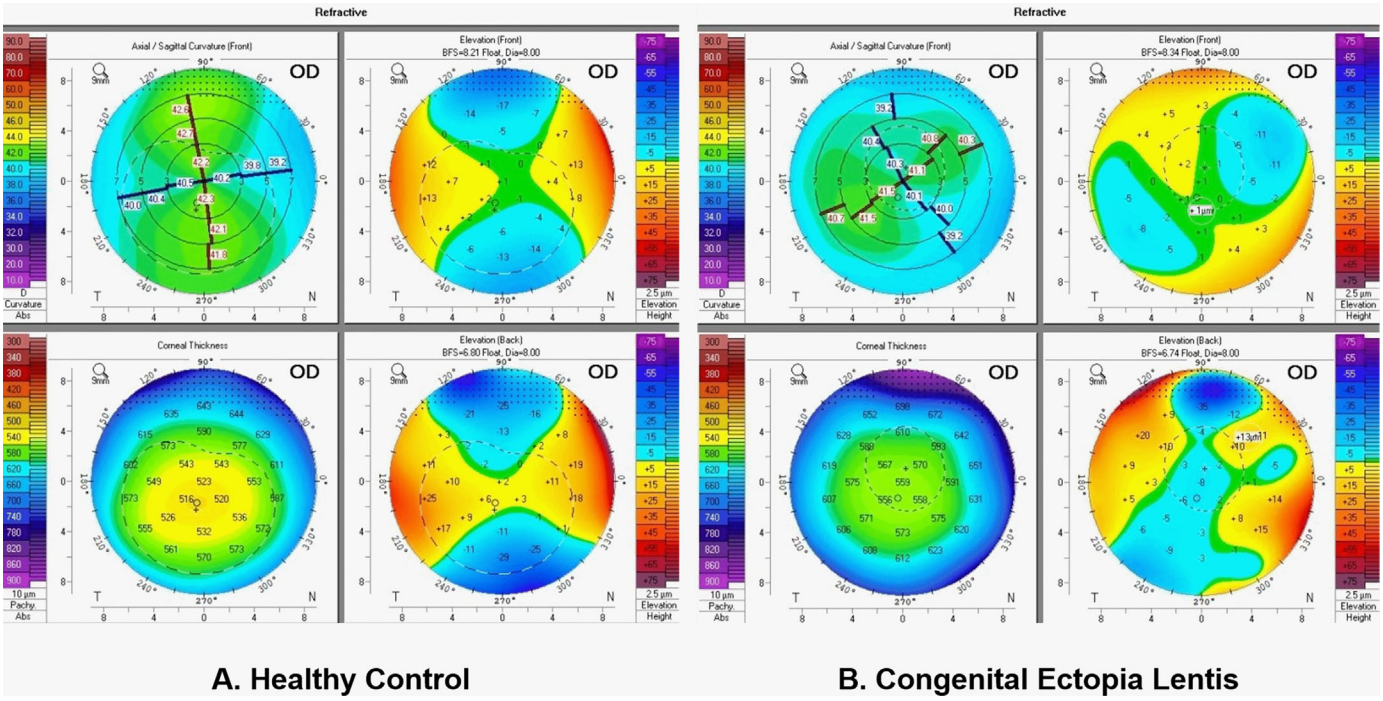

Figure 1. Comparison of the Pentacam-4 refractive maps in the patients with congenital ectopia lentis and controls.

Corneal Higher-Order Aberrations

The characteristics of the HOAs of interest are shown in Table 2 and Figure 2. The patients with CEL had lower anterior and total corneal spherical aberrations and larger posterior surface spherical aberration; among them, the anterior and total corneal horizontal coma (z 3, 1) of the CEL group was larger than that of controls (for anterior corneal horizontal coma: 0.22 ± 0.18 for CEL versus −0.05 ± 0.14 for controls, $P < 0.001$, for total corneal horizontal coma: 0.24 ± 0.18 for CEL versus −0.05 ± 0.14 for controls, $P < 0.001$). Supplementary Material and Figure 3 showed that age-specific distribution of corneal HOAs and the results shows that the anterior and total corneal surface of horizontal coma of CEL in each age group was larger than that in the controls (all $P < 0.05$). For patients with CEL of ages 10–20 years and ages >20 years, the anterior surface of vertical coma was lower than that of the controls (−0.20 ± 0.32 vs. −0.02 ± 0.24 µm, $P = 0.031$; and −0.06 ± 0.20 vs. 0.10 ± 0.22 µm, $P = 0.047$), for patients with CEL of ages <10 years and ages 10–20 years, the primary spherical aberration of anterior surface and total cornea was lower than that of the controls (all $P < 0.001$).

According to the scatter plot and the Pearson correlation analysis are shown in Figure 4, the horizontal coma of the anterior corneal and total surface in patients with CEL were negatively associated with age

translational vision science & technology

Downloaded from abstracts.iovs.org on 04/25/2024

Table 2. Comparisons of Corneal Higher-Order Aberrations of Patients in the CEL and Control Groups

Group	CEL	Control	*P* Value
RMS HOA (CF)	0.46 ± 0.16	0.46 ± 0.15	0.872
RMS HOA (CB)	0.20 ± 0.47	0.21 ± 0.13	0.454
RMS HOA (cornea)	0.49 ± 0.18	0.47 ± 0.18	0.533
Q Value CF	−0.41 ± 0.17	−0.32 ± 0.13	0.001
Z (3, 3) CF	0.00 ± 0.11	−0.02 ± 0.11	0.183
Z (3, 1) CF	0.22 ± 0.17	−0.05 ± 0.14	<0.001
Z (3, −1) CF	−0.13 ± 0.26	−0.01 ± 0.23	0.005
Z (3, −3) CF	−0.03 ± 0.13	−0.05 ± 0.12	0.470
Z (3, 3) CB	0.01 ± 0.07	0.02 ± 0.04	0.247
Z (3, 1) CB	0.01 ± 0.03	0.00 ± 0.03	0.950
Z (3, −1) CB	0.01 ± 0.05	0.01 ± 0.05	0.805
Z (3, −3) CB	−0.04 ± 0.08	−0.04 ± 0.06	0.690
Z (3, 3) cornea	0.02 ± 0.14	−0.00 ± 0.12	0.443
Z (3, 1) cornea	0.24 ± 0.18	−0.05 ± 0.14	<0.001
Z (3, −1) cornea	−0.14 ± 0.26	−0.00 ± 0.23	0.002
Z (3, −3) cornea	−0.08 ± 0.14	−0.09 ± 0.13	0.651
Z (4, 0) CF (um)			
Mean ± SD	0.15 ± 0.08	0.27 ± 0.08	<0.001
Positive (*n*)	58	75	
Negative (*n*)	2	0	
Z (4, 0) CB (um)			
Mean ± SD	−0.13 ± 0.03	−0.15 ± 0.03	<0.001
Positive (*n*)	0	0	
Negative (*n*)	60	75	
Z (4, 0) cornea (um)			
Mean ± SD	0.10 ± 0.09	0.23 ± 0.09	<0.001
Positive (*n*)	55	75	
Negative (*n*)	5	0	

RMS(HOA), total high-order aberrations root main square; CF, anterior corneal surface; CB, posterior corneal surface; cornea, total corneal surface; Z (4, 0), primary spherical aberration; Z (3, 3), oblique trefoil; Z (3, 1), horizontal coma; Z (3, −1), vertical coma; Z (3, −3), vertical trefoil; Z (4, 0), primary spherical aberration.

(r = −0.30, $P = 0.022$, r = −0.30, $P = 0.021$, respectively). The spherical aberrations of anterior and total corneal surface were positively correlated with age (for anterior corneal surface: r = 0.56, $P < 0.001$, for total corneal surface: r = 0.51, $P < 0.001$).

Discussion

In our study, the Q value in the CEL group was higher negative than that of the controls, and a significant difference in higher-order aberrations of the cornea between patients with CEL and the controls was detected. Compared to the controls, the patients with CEL had a higher horizontal coma and lower primary spherical aberrations.

It has been reported that corneal parameters of CEL were significant different with healthy subjects.[8] A previous study has suggested that the density of corneal elastic microfibrils is significantly reduced and the corneal central collagen fibrils are disorganized when an FBN1 mutation occurs.[9] For CEL, whose main cause is an FBN1 mutation, it is reasonable that the corneal structure and higher order corneal aberrations may have special characteristics. In this study, horizontal coma and primary spherical aberrations in patients with CEL were significantly different from the controls.

To our knowledge, HOA is one of the causes of blurred retinal imaging and could lead to the decrease of visual quality.[10] In our study, the horizontal coma of anterior and the whole corneal surface in the CEL

translational vision science & technology

Downloaded from abstracts.iovs.org on 04/25/2024

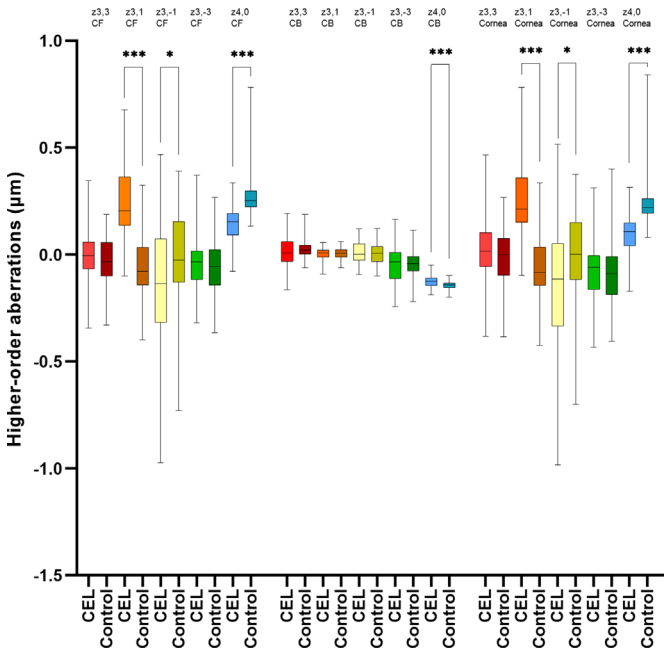

Figure 2. Comparisons of the HOAs of the cornea in the CEL and control groups. Z (3, 1), horizontal coma; Z (3, −1), age coma; Z (3, 3), oblique trefoil; Z (3, −3), vertical trefoil; Z (4, 0), primary spherical aberration; CF,= front corneal surface; CB, back corneal surface; cornea, total corneal surface.

group were larger than that in the control group, and such changes existed in each age group. In contrast, the vertical coma of the anterior surface and the total corneal surface of patients with CEL was significantly lower than that of the controls; when grouped by age, such differences also appeared in patients with CEL older than 10 years of age. Although larger horizontal coma reduced visual image quality, higher vertical coma was demonstrated to enhance the depth of focus.[11] Findings above may be the reasons why patients with CEL have low visual acuity even after timely surgery. Considering quite a few studies have confirmed that HOA is associated with the development of amblyopia,[12–16] the patients with CEL who experience adverse visual effects due to an enlarged horizontal coma could theoretically attempt to mitigate this effect by using rigid gas permeable contact lenses. In addition, in recent studies, Liao et al. suggested that HOA of patients with amblyopia can be corrected by using a real-time closed-loop adaptive optics perceptual learning system,[17] Tan et al. pointed out that fitting rigid gas permeable contact lenses and reverse geometry rigid gas permeable contact lens can effectively decrease HOAs of individuals induced by Lasik surgery by eliminating the irregularity and dissymmetry on the anterior corneal surface.[18,19] Hence, for patients with CEL, the methods mentioned above can also be used to reduce the adverse visual effects caused by HOAs.

In this study, the negative Q value of the anterior corneal surface was significantly larger in patients with CEL than in normal controls. Corneal Q value, the parameter to describe the aspheric morphology of the anterior corneal surface, representing the degree of discrepancy between the curvature of the central and paracentral corneal regions. The normal human cornea is transversely ellipsoidal, steep in the center and flat at the periphery.[20] Our study suggested that the cornea may be flatter in patients with CEL. Other studies have concluded that the flattened cornea in patients with CEL may be related to the morphological abnormalities in the elastic components caused by fibrin-1 mutation in patients with CEL, which can lead to an extraneous stretch of the cornea and eyeball, resulting in a flattened and thinner cornea.[21]

In our study, we found that patients in the CEL group had a lower value of spherical aberration than that in the controls. Spherical aberration is a major component of HOA and has a significant impact on optical quality, but spherical aberration in the human eye can be clinically modifiable with aspheric intraocular lens (IOLs), making it one of the most crucial factors for clinicians to consider in their preoperative IOL selection options.[22] Previous studies have concluded that in order for patients to have better visual quality after surgery, their postoperative residual spherical aberration should be preserved at 0.1 um, although current clinicians tend to select aspheric IOLs for patients with conventional cataract with a primary spherical aberration of −0.2 um or −0.27 um based on their corneal characteristics.[23] In our study, there was a significant difference in spherical aberration between the CEL group and the control group; the mean value of the total corneal primary spherical aberration was 0.06 ± 0.08 um in the ≤10 years old group, and the mean value of primary spherical aberration in the 10–20 years old group was 0.12 ± 0.08. The above findings revealed that the patients with CEL in each age group had a lower corneal primary spherical aberration than the controls. This result suggested that for patients with CEL, especially in the younger age group, the residual primary spherical aberration obtained with the conventional negative spherical aberration compensated aspheric IOL was much lower than 0.1 um, which would reduce their postoperative visual quality. It is also worth noting that our results also showed that approximately 2 of 60 patients with CEL (3.33%) had negative anterior corneal spherical aberration and 5 of 60 (8.33%) had negative spherical aberration of total corneal, which was not detected in the

translational vision science & technology

Downloaded from abstracts.iovs.org on 04/25/2024

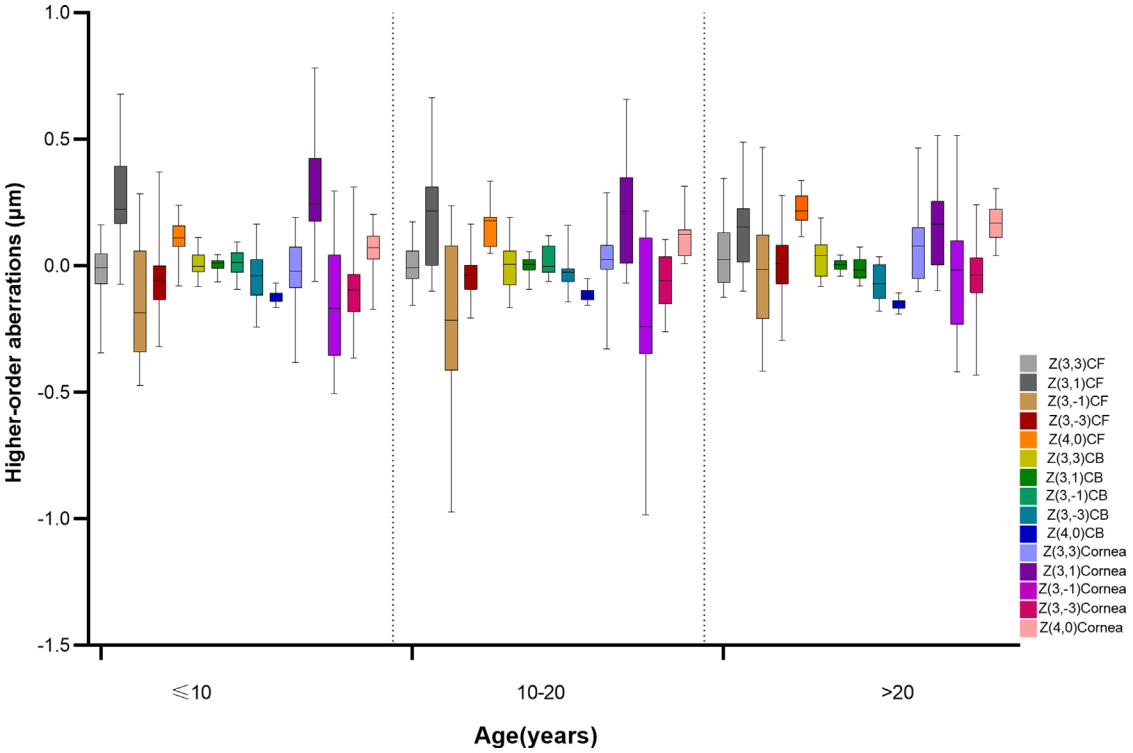

Figure 3. Comparisons of the HOAs according to age in patients in ectopia lentis. (Z (3, 1), horizontal coma; Z (3, −1), vertical coma; Z (3, 3), oblique trefoil; Z (3, −3), vertical trefoil; Z (4, 0), primary spherical aberration; CF, front corneal surface; CB, back corneal surface; cornea, total corneal surface.

normal control group. However, the above findings are still theoretical and not directly associated with IOL selection, the findings cannot confirm this retrospective study that which will need to be confirmed in future prospective studies, but nevertheless, the results remind us of the need to pay attention to the relationship between IOLs and HOA in patients with CEL.

As shown in Figure 2, we also found that the distribution of HOAs in the anterior surface of the cornea was consistent with that of the whole surface, a result similar to Dubbelman et al.'s conclusion that the HOAs of the posterior corneal surface in normal subjects represent a small fraction of those of total cornea.[24] Meanwhile, as shown in Figure 4, the horizontal coma of the anterior cornea decreased with an increase in age, whereas the anterior and total corneal primary spherical aberration increased with an increase in age, which suggested that in patients with CEL, the primary spherical aberration of anterior and total corneal surface have a similar trend, whereas the horizontal coma in the posterior corneal surface is stable and does not change with age. The result may be attributed to the fact that our study was a cross-sectional rather than a longitudinal study, The older age of our included patients may be due to their later ocular onset, so the cornea is relatively more stable and thus the horizontal coma does not increase significantly. However, more longitudinal studies are needed in the future to further investigate the relationship between age and corneal horizontal coma.

There are some limitations in this study. First, although the patients came from different regions of China, the majority of them were from southern China, which is not representative of the entire CEL patient population. Second, this paper is a cross-sectional study, and more relevant longitudinal studies are still needed in the future to better understand the distribution and changing trend of higher-order aberration in patients with CEL. However, this study is important as the first large sample size study describing the distribution of HOAs in Chinese patients with CEL, despite the above limitations.

In conclusion, the results of this study indicate that the patients with CEL had higher corneal horizontal coma and lower corneal primary spherical aberrations than healthy controls, which suggests more attention should be paid for formulating treatment strategies in patients with CEL.

translational vision science & technology

Downloaded from abstracts.iovs.org on 04/25/2024

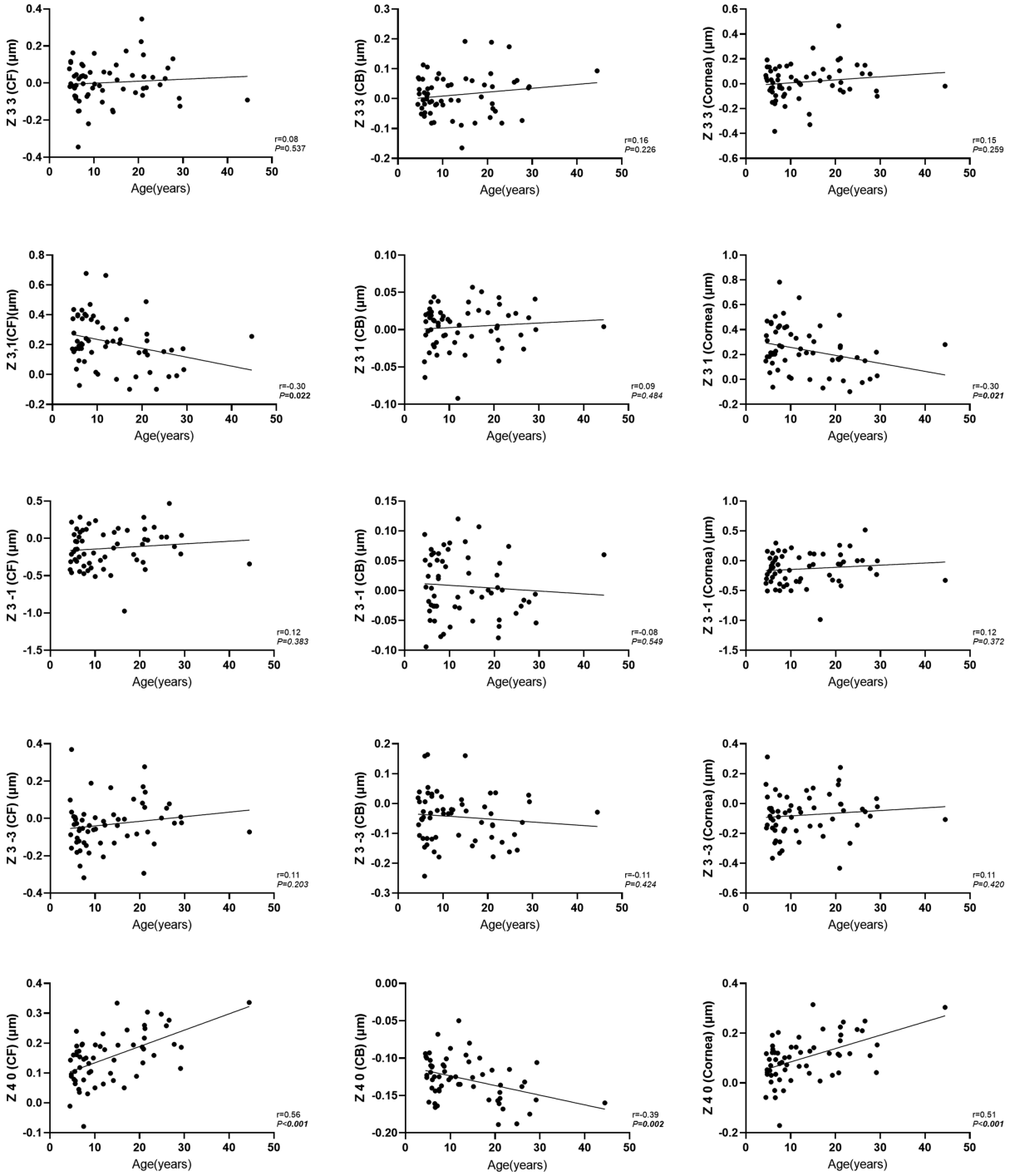

Figure 4. Correlations between 5 HOAs and age. Z (3, 1), horizontal coma; Z (3, −1), vertical coma; Z (3, 3), oblique trefoil; Z (3, −3), vertical trefoil; Z (4, 0), primary spherical aberration; CF, front corneal surface; CB, back corneal surface; cornea, total corneal surface.

translational vision science & technology

Downloaded from abstracts.iovs.org on 04/25/2024

Acknowledgments

The authors thank the staff in the Clinical Research Center of Zhongshan Ophthalmic Center.

Supported by National Natural Science Foundation of China (81873673 and 81900841), the Guang-Dong Basic and Applied Basic Research Foundation (2021A1515011673), and the Young Teachers Training Program of Sun Yat-sen University(20ykpy143).

Contributors: G.J. and D.Z. designed the study, initiated the collaborative project, and revised the paper. H.Y. and Z. Liu were responsible for data acquisition, data analysis, interpretation, and drafting the manuscript. H.Y., Q.C., and Z. Lian cleaned and analyzed the data. X.Z. and C.A.Y. were responsible for administrative, technical, or logistic support. D.Z. and G.J. had final approval of the paper.

Disclosure: **H. Ye**, None; **Z. Liu**, None; **Q. Cao**, None; **C.A. Young**, None; **Z. Lian**, None; **X. Zhang**, None; **D. Zheng**, None; **G. Jin**, None

* HY and ZL should be considered co-first authors.

References

1. Dureau P. Pathophysiology of zonular diseases. *Curr Opin Ophthalmol*. 2008;19:27–30.
2. Gehle P, Goergen B, Pilger D, et al. Biometric and structural ocular manifestations of Marfan syndrome. *PLoS One*. 2017;12:e0183370.
3. Millodot M, Sivak J. Contribution of the cornea and lens to the spherical aberration of the eye. *Vision Res*. 1979;19:685–687.
4. Cheng X, Thibos LN, Bradley A. Estimating visual quality from wavefront aberration measurements. *J Refract Surg*. 2003;19:S579–S584.
5. Kaswin G, Rousseau A, M'Garrech M, et al. Optical aberrations in patients with recurrent herpes simplex keratitis and apparently normal vision. *Br J Ophthalmol*. 2013;97:1113–1117.
6. Shimizu E, Yamaguchi T, Yagi-Yaguchi Y, et al. Corneal Higher-Order Aberrations in Infectious Keratitis. *Am J Ophthalmol*. 2017;175:148–158.
7. Yamaguchi T, Shimizu E, Yagi-Yaguchi Y, et al. A Novel Entity of Corneal Diseases with Irregular Posterior Corneal Surfaces: Concept and Clinical Relevance. *Cornea*. 2017;36(Suppl 1):S53–S59.
8. Zhang Y, Jin G, Young CA, et al. Analysis of Corneal Astigmatism before Surgery in Chinese Congenital Ectopia Lentis Patients. *Curr Eye Res*. 2018;43:972–976.
9. White TL, Lewis P, Hayes S, et al. The Structural Role of Elastic Fibers in the Cornea Investigated Using a Mouse Model for Marfan Syndrome. *Invest Ophthalmol Vis Sci*. 2017;58:2106–2116.
10. Liao X, Lin J, Tian J, et al. Evaluation of Optical Quality: Ocular Scattering and Aberrations in Eyes Implanted with Diffractive Multifocal or Monofocal Intraocular Lenses. *Curr Eye Res*. 2018;43:696–701.
11. Nanavaty MA, Spalton DJ, Marshall J. Effect of intraocular lens asphericity on vertical coma aberration. *J Cataract Refract Surg*. 2010;36:215–221.
12. Plech AR, Pinero DP, Laria C, Aleson A, Alio JL. Corneal higher-order aberrations in amblyopia. *Eur J Ophthalmol*. 2010;20:12–20.
13. Prakash G, Sharma N, Chowdhary V, Titiyal JS. Association between amblyopia and higher-order aberrations. *J Cataract Refract Surg*. 2007;33:901–904.
14. Prakash G, Sharma N, Saxena R, et al. Comparison of higher order aberration profiles between normal and amblyopic eyes in children with idiopathic amblyopia. *Acta Ophthalmol*. 2011;89:e257–e262.
15. Vincent SJ, Collins MJ, Read SA, Carney LG. Monocular amblyopia and higher order aberrations. *Vision Res*. 2012;66:39–48.
16. Zhao PF, Zhou YH, Wang NL, Zhang J. Study of the wavefront aberrations in children with amblyopia. *Chin Med J (Engl)*. 2010;123:1431–1435.
17. Liao M, Zhao H, Liu L, et al. Training to improve contrast sensitivity in amblyopia: correction of high-order aberrations. *Sci Rep*. 2016;6:35702.
18. Tan G, Chen X, Xie RZ, et al. Reverse geometry rigid gas permeable contact lens wear reduces high-order aberrations and the associated symptoms in post-LASIK patients. *Curr Eye Res*. 2010;35:9–16.
19. Tan G, Yang J, Chen X, He H, Zhong X. Changes in wave-front aberrations after rigid gas permeable contact lens fitting in post-laser in situ keratomileusis patients with visual complaints. *Can J Ophthalmol*. 2010;45:264–268.
20. Zhang Z, Wang J, Niu W, et al. Corneal asphericity and its related factors in 1052 Chinese subjects. *Optom Vis Sci*. 2011;88:1232–1239.
21. Sultan G, Baudouin C, Auzerie O, et al. Cornea in Marfan disease: Orbscan and in vivo confocal microscopy analysis. *Invest Ophthalmol Vis Sci*. 2002;43:1757–1764.
22. Lian HF, Tang X, Song H. The influence of preoperative corneal spherical aberration on relatively

translational vision science & technology

Downloaded from abstracts.iovs.org on 04/25/2024

personalized implantation of aspheric intraocular lens. *Zhonghua Yan Ke Za Zhi*. 2010;46:410–414.
23. Tan QQ, Lin J, Tian J, Liao X, Lan CJ. Objective optical quality in eyes with customized selection of aspheric intraocular lens implantation. *BMC Ophthalmol*. 2019;19:152.
24. Dubbelman M, Sicam VA, van der Heijde RG. The contribution of the posterior surface to the coma aberration of the human cornea. *J Vis*. 2007;7(10):1–8.

translational vision science & technology

Downloaded from abstracts.iovs.org on 04/25/2024