Genetics

Clinical and Genetic Landscape of Ectopia Lentis Based on a Cohort of Patients From 156 Families

Dongwei Guo, Shiqiang Li, Xueshan Xiao, Yi Jiang, Yingwei Wang, Guangming Jin, Junwen Wang, Jiamin Ouyang, Xiaoyun Jia, Wenmin Sun, Panfeng Wang, Danying Zheng, and Qingjiong Zhang

State Key Laboratory of Ophthalmology, Zhongshan Ophthalmic Center, Sun Yat-Sen University, Guangdong Provincial Key Laboratory of Ophthalmology and Visual Science, Guangzhou, China

Correspondence: Qingjiong Zhang, State Key Laboratory of Ophthalmology, Zhongshan Ophthalmic Center, Sun Yat-Sen University, 54 Xianlie Road, Guangzhou 510060, China; zhangqji@mail.sysu.edu.cn. Danying Zheng, State Key Laboratory of Ophthalmology, Zhongshan Ophthalmic Center, Sun Yat-Sen University, 54 Xianlie Road, Guangzhou 510060, China; zhengdyy@163.com.

Received: August 24, 2023
Accepted: December 19, 2023
Published: January 8, 2024

Citation: Guo D, Li S, Xiao X, et al. Clinical and genetic landscape of ectopia lentis based on a cohort of patients from 156 families. *Invest Ophthalmol Vis Sci.* 2024;65(1):20. https://doi.org/10.1167/iovs.65.1.20

Purpose. To extend the mutation spectrum and explore the characteristics of genotypes and ocular phenotypes in ectopia lentis (EL).

Methods. Variants in all 14 reported EL-associated genes were selected from in-house data sets as well as literature review, and available clinical data were analyzed.

Results. Likely pathogenic variants in three genes were identified in 156 unrelated families with EL from the in-house cohort, of which 97.4% resulted from variants in *FBN1*, whereas the remaining were caused by variants in *ADAMTSL4* (1.3%) and *LTBP2* (1.3%). A comparative analysis of the in-house data and literature review suggested several characteristics: (1) a higher proportion of cysteine involvement variants in *FBN1*, either variants introducing or eliminating cysteine, and an earlier diagnosis age were presented in our cohort than in published literature; (2) the axial length (AL) and refractive error increased more rapidly with age in preschool EL children than normal children, and the increased rate of AL was slower in patients with surgery than those without surgery; (3) aberrant astigmatism was common in EL; and (4) worse vision and earlier onset age were observed in patients with non-*FBN1* variants (all $P < 0.05$).

Conclusions. Variants in *FBN1* are the predominant cause of EL, with the most common cysteine involvement variants. Early-stage EL manifests refractive error but gradually converts to axial myopia through defocus introduced by lens dislocation. Aberrant astigmatism is a suggestive sign of EL. Non-*FBN1* variants cause early-onset and severe phenotypes. These results provide evidence for early diagnosis as well as timely treatment for EL.

Keywords: ectopia lentis, *FBN1*, genotype, phenotype, Marfan syndrome

Congenital ectopia lentis (EL) is a rare but severe disease that manifests as lens dislocation from a normal position, with a prevalence of 6.4/100,000.[1] The ophthalmic complications of EL range broadly from myopia, astigmatism, amblyopia, and glaucoma to retinal detachment.[2] The complex phenotypes of EL not only lead to severe visual impairments but also affect quality of life, which are closely associated with different gene defects.[3]

To date, several genes have been reported potentially associated with EL (Fig. 1A). As reported in the literature, variants in *FBN1* account for the highest proportion in all EL-associated variants.[4] Variants in *FBN1* are closely related to Marfan syndrome, which is an autosomal dominant disorder and combines with ocular, cardiovascular, skeletal, and dermal complications.[5] Variants in *ADAMTSL4* are related to isolated EL and EL et pupillae. Variants in *ADAMTS17*, *ADAMTS10*, and *LTBP2* were reported closely associated with microspherophakia and Weill–Marchesani syndrome.[6] Variants in *CBS* were identified in association with homocystinuria,[7] and variants in *SUOX* can cause sulfite oxidase deficiency.[8] In addition to these seven genes, which have been widely reported and recognized as the causal genes for EL, there are also seven additional genes that have been reported to cause syndromes that include EL. *ASPH* is related to Traboulsi syndrome,[9–12] *COL18A1* is related to Knobloch syndrome,[13] *CPAMD8* is related to anterior segment dysgenesis,[14] *PAX6* is related to aniridia,[15] *VSX2* is related to microphthalmia,[16] *TGFB2* is related to Loeys–Dietz syndrome,[17] and *MTHFR* is related to homocystinuria.[18] Variants in these genes with lens subluxation were reported sporadically.

Identifying the ocular features of EL correctly facilitates early diagnosis. Unfortunately, there is lack of sufficient knowledge on how ocular characteristics develop with the progressive dislocation of the lens. Furthermore, there is a scarcity of systematic summaries regarding different EL-associated genes. Hence, this study aims to investigate the clinical and genetic landscape of Chinese patients with EL with the combination of a literature review. Additionally, this research also tries to identify potential genotype–phenotype associations in EL-associated genes, which helps provide effective genetic counseling and aids

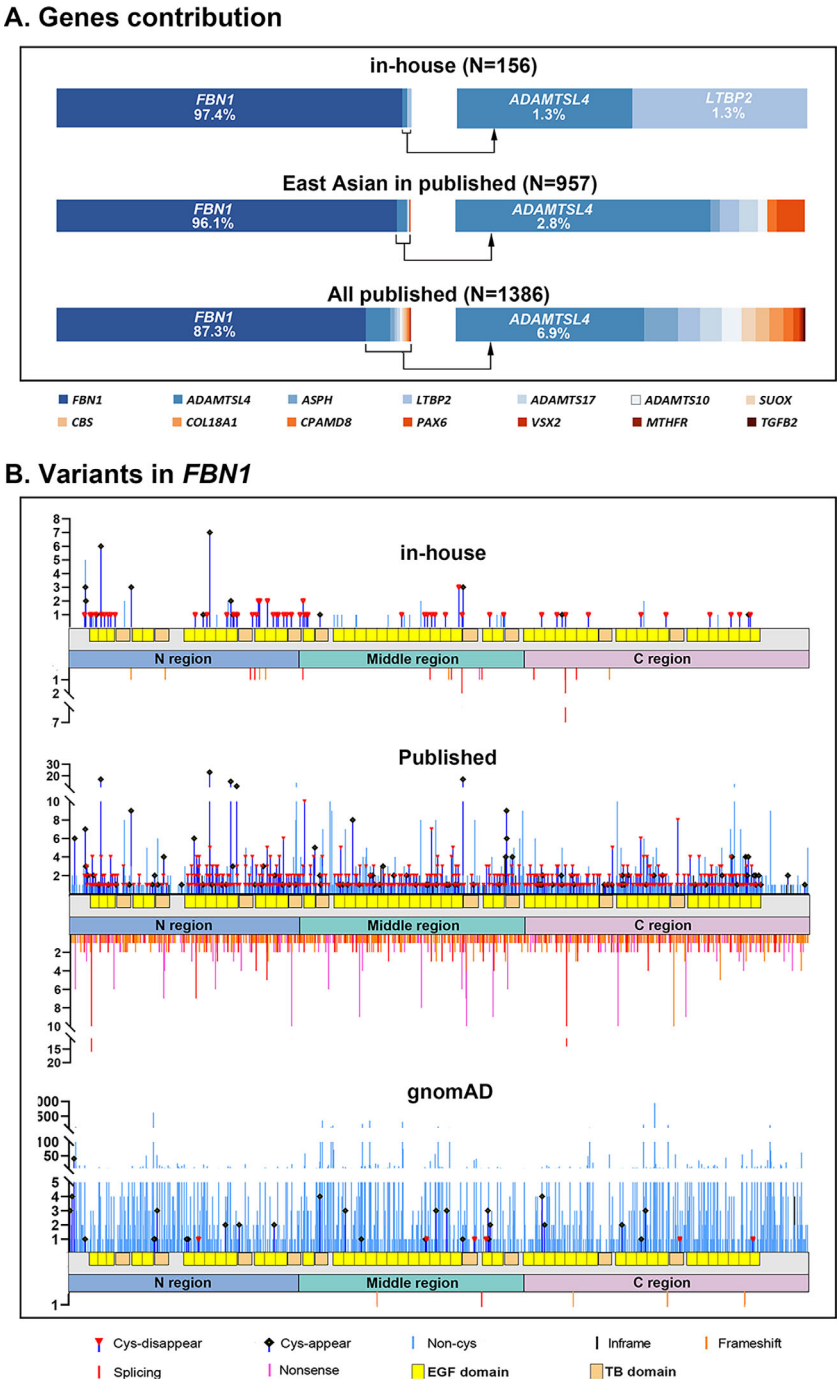

Figure 1. The contribution of EL-associated genes and the distribution of *FBN1* variants. (**A**) The contribution of EL-associated genes in the in-house data sets and published literature. (**B**) The distribution and frequency of *FBN1* variants in our cohort, published literature, and the gnomAD database. Cys-disappear: missense variants that eliminate cysteine; Cys-appear: missense variants that introduce a new cysteine; Non-cys-missense: missense variants without cysteine substitution.

in early diagnosis, thereby assisting in making treatment strategies.

Patients and Methods

Patients

Patients diagnosed with EL were enrolled from the Pediatric and Genetic Clinic, Zhongshan Ophthalmic Center, Guangzhou, China. Written informed consent was obtained from participants or their guardians in compliance with the Declaration of Helsinki. Ethical approval was obtained from the institutional review board of the Zhongshan Ophthalmic Center (2011KYNL012). Clinical data were collected and genomic DNA was extracted from the peripheral venous blood according to the method previously described.[19]

Variant Evaluation

The variants in all reported EL-associated genes (*FBN1*, *ADAMTSL4*, *LTBP2*, *ADAMTS10*, *ADAMTS17*, *SUOX*, *CBS*, *ASPH*, *COL18A1*, *CPAMD8*, *PAX6*, *VSX2*, *MTHFR*, and

TGFB2) were collected from an in-house exome sequencing data set, which includes targeted exome sequencing and whole-exome sequencing. The procedures for sequencing and variant filtering were according to the method as previously reported.[20,21] The variants were analyzed as follows: five in silico tools, including REVEL, CADD, SIFT, Polyphen-2, and PROVEN, were used to predict the pathogenicity of missense variants. Three tools, including varSEAK, HSF, and Alamut Visual, were used to predict the splicing variants. All variants were confirmed by Sanger sequencing and cosegregation.

The evaluation of pathogenicity of variants was according to the American College of Medical Genetics and Genomics and the Association for Molecular Pathology standards.[22] To obtain a comprehensive genetic and clinical landscape of EL, 71 families reported by our team were also included in this study.[23,24]

Variant Classification

Variants in the *FBN1* gene were classified into several subgroups according to categories defined in a previous study.[25] Missense variants in *FBN1* were separated as cysteine involving (cys) and the other (non-cys). The former one includes eliminating cysteine (cys-disappear) and introducing a new cysteine (cys-appear).

Ocular Examination

The severe EL group was defined as the edge of lens could be seen in a normal pupil without dilation. Mild EL was defined as the edge of lens could be seen only after pupil dilation. Astigmatism was expressed as a positive cylinder form, and when its value was >2 D, then it was recognized as severe astigmatism. The astigmatism axis was classified as with-the-rule (WTR, plus cylinder axis 90 ± 15 degrees), against-the-rule (plus cylinder axis 180 ± 15 degrees), and oblique (plus cylinder axis 15 to 75 degrees or 105 to 165 degrees).

Literature Review

A detailed review of all reported EL-associated genotypes and phenotypes was performed based on a search conducted until November 1, 2022, on HGMD and PubMed.

Statistical Analysis

Mann–Whitney *U* test was applied to compare the continuous variables of cohort characteristics between two groups. Kruskal–Wallis test was used to compare data in more than two groups. The χ^2 test or Fisher's exact test was applied in the classified variables in different genotype groups. A statistically significant difference was considered when $P < 0.05$. The data analysis was performed using SPSS for Windows version 25.0 (SPSS/IBM, Chicago, IL, USA).

Results

Mutation Spectrum of EL

In this cohort, 156 (86.7%) of 180 EL families were detected with likely pathogenic variants in EL-associated genes. For this study, all 186 patients from these 156 families were included. By comprehensive literature review, clinical data from 1386 EL families with all 14 reported EL-associated genes (*FBN1*, *ADAMTSL4*, *LTBP2*, *ADAMTS10*, *ADAMTS17*, *SUOX*, *CBS*, *ASPH*, *COL18A1*, *CPAMD8*, *PAX6*, *VSX2*, *MTHFR*, and *TGFB2*) were also included for analysis (Fig. 1A). A summary of all detected likely pathogenic variants in the in-house cohort is provided in Supplementary Table S1. In total, 125 variants were identified, with 94.4% variants in *FBN1* (118/125). There were 32 novel variants, including 25 in *FBN1*, 4 in *ADAMTSL4*, and 3 in *LTBP2*.

The contribution of variants in these genes to EL in the in-house data sets and published literature is presented in Figure 1A. In this cohort, variants in *FBN1* were the most frequent genetic defects, accounting for 97.4% (152/156) of the EL families, followed by *ADAMTSL4* (1.3%, 2/156) and *LTBP2* (1.3%, 2/156). In published cases of EL, variants in *FBN1* accounted for the highest proportion in all populations (87.3%, 1210/1386) and the East Asian (EA) population (96.1%, 920/957) as well. *ADAMTSL4* was the next most frequent gene in all populations (6.9%, 95/1386) and the EA population (2.8%, 27/957).

Distribution and Genotypes of *FBN1* Variants

The distribution of *FBN1* variants in the in-house data sets, all available data from published literature, and the gnomAD database is presented in Figure 1B, in which the former two groups refer to likely pathogenic variants while those in gnomAD include all variants. In the in-house data sets, most *FBN1* missense variants were located in the EGF domain (77.0%, 117/152). In total, 52.6% (80/152) of the variants were found in N-terminal region, 29.6% (45/152) in the middle region, and the remaining 17.8% (27/152) in C-terminal region. Additionally, the distribution of *FBN1* variants exclusively within the EA population, obtained from both published literature and the gnomAD database, is depicted in Supplementary Figure S1. The variants of *FBN1* present a similar distribution between the EA population and the global population.

The contributions of distinct genotypes were significantly different when comparing the in-house EL cohort with both the EA and all population data in the published literature and gnomAD database (Fig. 2A). In our cohort, 82.2% families (125/152) had missense variants (including cys-disappear, cys-appear, and non-cys variants), while 17.8% (27/152) had truncation variants. Among all genotypes, cys-missense variants (cys-disappear and cys-appear) were the most common subtype in our cohort, while truncation variants and non-cys missense variants were more common in published literature. In the gnomAD database, the non-cys missense variants were predominant in all populations (98.8%) and the EA population (99.3%). Besides, the proportion of cys-appear variants was significantly higher in the in-house EL cohort (21.7%) compared to the published literature and gnomAD for both all populations and the EA population (all $P < 0.0001$). There was no significant difference in the proportion of cys-appear variants within the gnomAD data sets when comparing all populations to the EA population ($P = 0.31$).

Cohort Demographics in Patients With *FBN1* Variants

We included 182 patients from 152 families. The detailed demographic characteristics are shown in Table 1. In this EL cohort, the median age at diagnosis was 5.8 years. The median axial length (AL) was 25.6 mm and the median spherical equivalent (SE) was −10.6 D. High myopia was

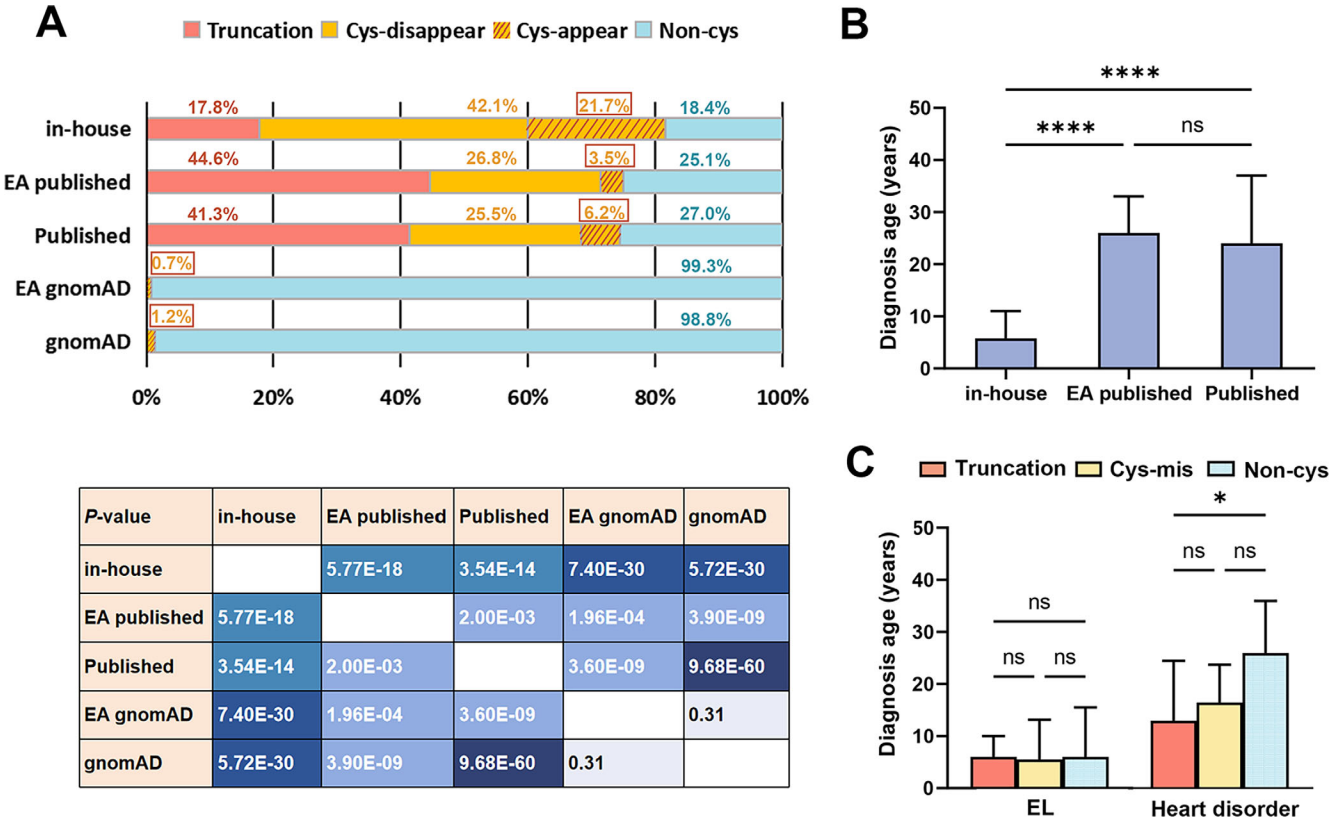

P-value	in-house	EA published	Published	EA gnomAD	gnomAD
in-house		5.77E-18	3.54E-14	7.40E-30	5.72E-30
EA published	5.77E-18		2.00E-03	1.96E-04	3.90E-09
Published	3.54E-14	2.00E-03		3.60E-09	9.68E-60
EA gnomAD	7.40E-30	1.96E-04	3.60E-09		0.31
gnomAD	5.72E-30	3.90E-09	9.68E-60	0.31	

Figure 2. The genotypes and diagnosis age of *FBN1* variants. (**A**) The proportion of different genotypes among the in-house datasets, the EA population, and the overall population as reported in published literature and gnomAD database. (**B**) The diagnosis age of patients in the in-house EL cohort compared to the EA population and the overall population as reported in the published literature. (**C**) The diagnosis age of EL or heart disorders in patients with different genotypes. $^{*}P < 0.05$, $^{****}P < 0.0001$.

Table 1. Demographic Characteristics of Patients with *FBN1* Variants

Patients	Value
Onset age, y	2.0 (0.5–4.0)
Diagnosis age, y	5.8 (3.0–11.0)
Visit age, y	7.4 (4.5–21.0)
Gender, female/male	85/97
Ocular biometrics, median (inter-quartile range)	
AL (mm)	25.6 (23.4–27.5)
K (D)	41.1 (39.5–42.3)
LT (mm)	4.0 (3.6–4.4)
BCVA (LogMAR)	0.5 (0.3–0.7)
AST (D)	3.3 (2.3–5.0)
SE (D)	−10.6 (−18.6 to −10.0)
CAST (D)	1.7 (1.1–2.4)
Refractive error, % (*n*)	
Severe AST	83.0 (78/94)
High myopia	81.4 (127/156)
Fundus lesions, % (*n*)	
Total	31.3 (31/99)
Myopia-related fundus changes	22.2 (22/99)
Retinal detachment	5.1 (5/99)
EL severity, % (*n*)	
Mild	31.6 (43/136)
Severe	68.4 (93/136)
Genotype, % (*n*)	
Missense	81.9 (149/182)
Truncation	18.1 (39/182)
Location, % (*n*)	
N region	52.2 (95/182)
Middle region	31.3 (57/182)
C region	16.5 (30/182)

AST, astigmatism; CAST, corneal astigmatism; K, keratometry; LT, lens thickness.

present in up to 81.4%, and the incidence of fundus lesions was 31.3%. Among the patients with fundus lesions, 5.1% of patients with EL had retinal detachment.

In comparison to patients reported in the published literature, it was observed that the diagnosis age of our in-house EL cohort was much earlier than that in both the overall population and the EA population (Fig. 2B, $P < 0.0001$). Among different genotypes in the EA population, there was no significant difference in the diagnosis age of EL itself (Fig. 2C). For patients with heart disorders, those with the truncation variants tended to be diagnosed earlier compared to those with non-cys missense variants (Fig. 2C, $P < 0.05$).

The characteristics of the anterior segment in EL are presented in Figure 3. Due to the dysplastic zonular fibers, the lens dislocated in various directions (Fig. 3A). Mild EL was inconspicuous before pupil dilation, but the changes in anterior chamber depth and the edge of the lens could be detected after full pupil dilation (Fig. 3B). In contrast, severe EL could be diagnosed more easily even without pupil dilation (Fig. 3C). There were some special forms of EL, such as lens coloboma (Fig. 3D), pupillary capture (Fig. 3E), or microspherophakia (Fig. 3F).

The characteristics of the fundus in EL are presented in Figure 4. It was observed that there were no obvious fundus abnormalities in early-stage of EL (Fig. 4A). However, with disease development, the fundus changed gradually, complicated by AL growth and high myopia-related lesions (Figs. 4B, 4C). For one patient with complete lens luxation into the vitreous chamber, high myopia-related changes and the lattice retinal degeneration were detected (Figs. 4D).

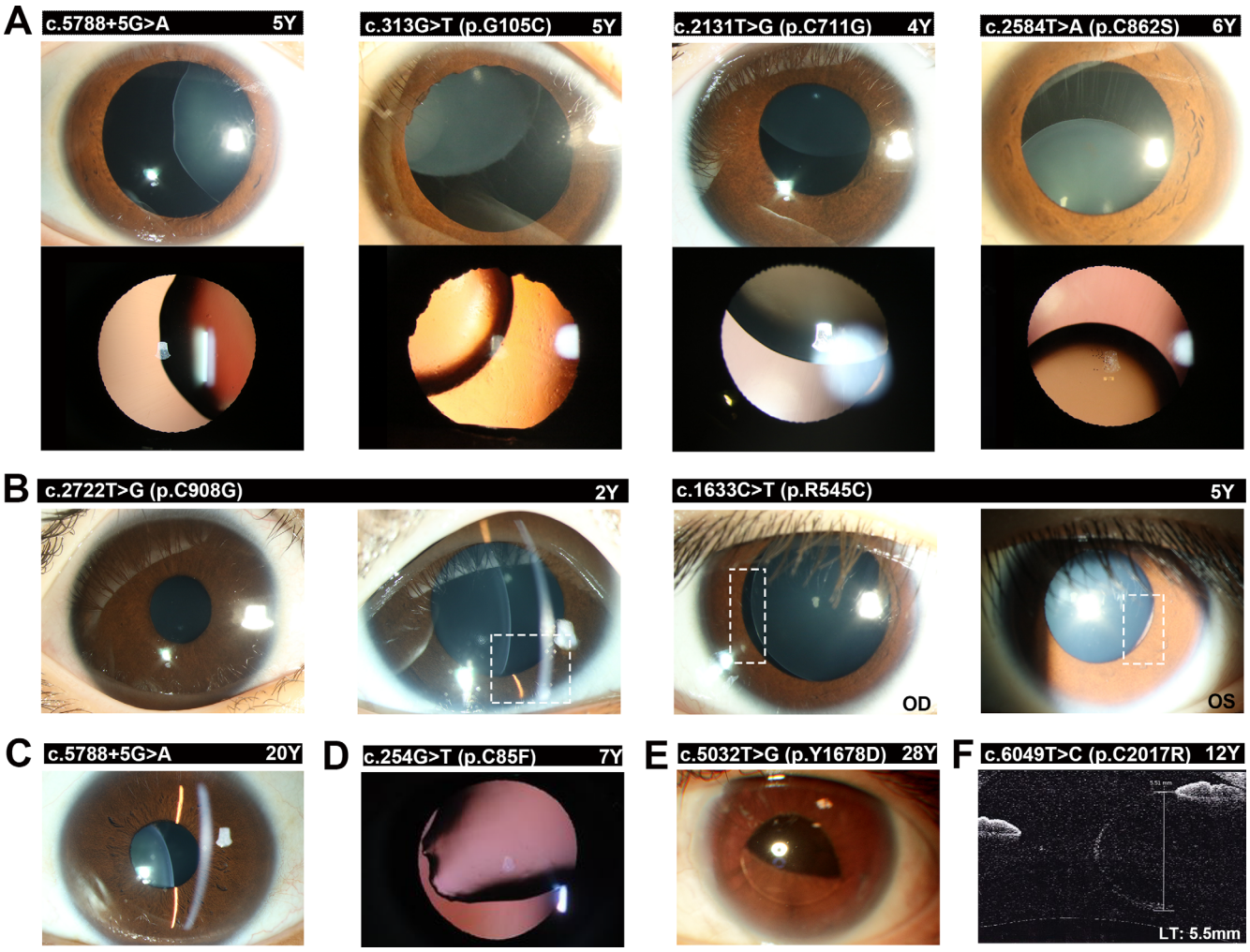

Figure 3. The characteristics of the anterior segment in EL. (**A**) The lens dislocated in different directions. (**B**) The manifestations of mild EL before and after pupil dilation (the *white lines* refer to signs of lens dislocation). (**C**) The severe EL before pupil dilation. (**D**) EL combined with lens coloboma. (**E**) EL combined with pupillary capture. (**F**) Microspherophakia detected by anterior segment optical coherence tomography. LT, lens thickness.

As the most serious vision loss complication, retinal detachment was observed in five patients (Figs. 4E–G).

Ocular Phenotypes in Patients With *FBN1* Variants

The continuous development of AL in preschool EL children compared to the age-matched individuals from the normal population[26–28] is depicted in Figure 5A. The AL in children with EL initially overlapped with normal children. However, with disease progression, the average AL in children with EL (aged 1.8–7.0 years) increased rapidly and deviated from the normal range by 2 to 3 years of age. The median AL for children with EL was 20.7 mm (95% confidence interval [CI], 18.4–23.0 mm) at 1.8 years old, reaching up to 28.7 mm (95% CI, 26.5–31.0 mm) at 7 years old. In comparison, normal children had a median AL of 21.3 mm (95% CI, 20.0–22.6 mm) at 1.8 years old, increasing to 23.0 mm (95% CI, 21.4–30.9 mm) at 7 years old. Comparing the continuous development of SE in preschool children with EL with age-matched individuals from the normal population (Fig. 5A),[26,29] severe refractive error was evident in EL even at an early stage. The correlation analysis further indicated that patients with EL with longer AL were associated with more severe refractive error (Fig. 5B, R = −0.441, $P < 0.0001$). Comparing the increased rate of AL in age-matched patients without surgery to those with surgery, the increased rate in patients without surgery (N-Surgery: 0.8 [0.2–1.1] mm/y) was significantly higher than that of those with surgery (Surgery: 0.2 [0.1–0.3] mm/y) (Fig. 5C, $P < 0.0001$).

A comparison between patients with microspherophakia to those without microspherophakia revealed that the microspherophakia group had a thicker lens ($P < 0.0001$), a higher degree of SE ($P < 0.001$), and an earlier diagnosis age ($P < 0.01$) (Fig. 6A). Compared to age-matched normal subjects,[30] the astigmatism in EL was significantly higher among different age groups (Fig. 6B, all $P < 0.0001$). Furthermore, differences were observed in the types of astigmatism axis between the EL group and the normal population,[30] as the WTR and oblique astigmatism were much common in the EL group (Fig. 6C, $P < 0.0001$). Patients with EL with severe astigmatism were more likely to be diagnosed at an early age (Fig. 6D, $P < 0.05$). Patients with severe EL tended to

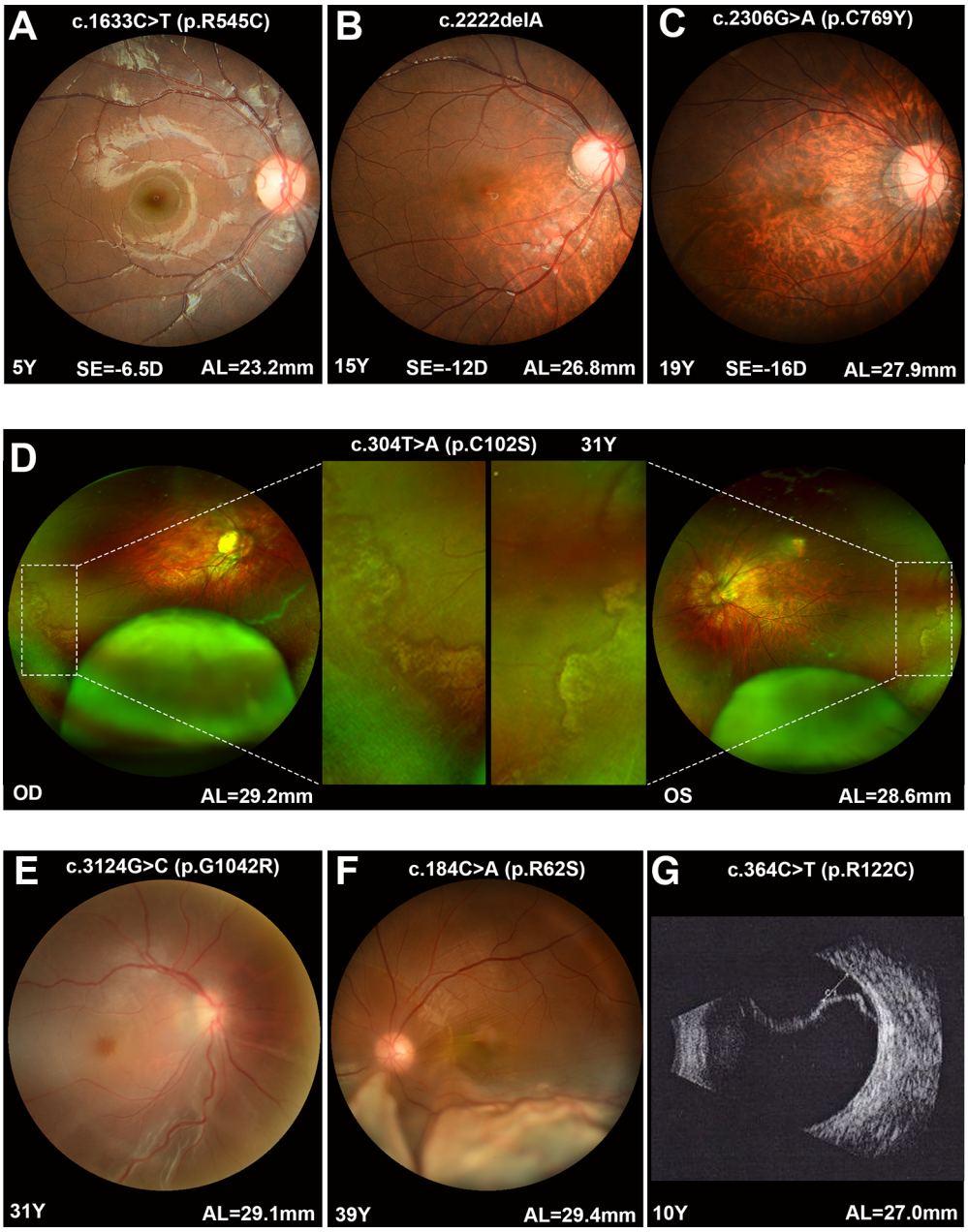

Figure 4. The characteristics of fundus in patients with EL. (**A**) The normal fundus. (**B**, **C**) The fundus presented high myopia-related changes, including a slanted optic disk, lacquer crack formation, and pigment mottling in the retina. (**D**) The posterior dislocation of the lens and lattice retinal degeneration. (**E–G**) The retinal detachment.

have worse best-corrected visual acuity (BCVA) and a higher degree of SE compared to those with mild EL (Fig. 6, all $P < 0.05$).

Genotype–Phenotype Analysis for EL-Associated Genes

The genotype–phenotype analysis for patients with *FBN1* variants from in-house data sets is presented in Table 2. Patients with variants in the C-terminal region were more likely to have longer ALs and flatter corneas than those with variants in other regions of *FBN1* ($P < 0.05$). Patients with cys-missense variants had a longer AL than those with non-cys-missense variants ($P < 0.05$).

It was also noted that patients with variants in non-*FBN1* genes presented severe phenotypes. For the two in-house patients detected with biallelic variants in *ADAMTSL4*, one patient was combined with retinal detachment and the other one had complete luxation of the lens. For the two in-house patients detected with biallelic variants in *LTBP2*, one was combined with complete luxation of lens and retinopathy, and the other one had severe EL and poor vision.

To investigate potential genotype–phenotype correlations in EL-associated genes comprehensively, all available data from published literature and the in-house cohort were included for analysis. The distribution of BCVA, AL, and SE with age among different EL-associated genes is presented in Figure 7A. As depicted in Figure 7B, compared to

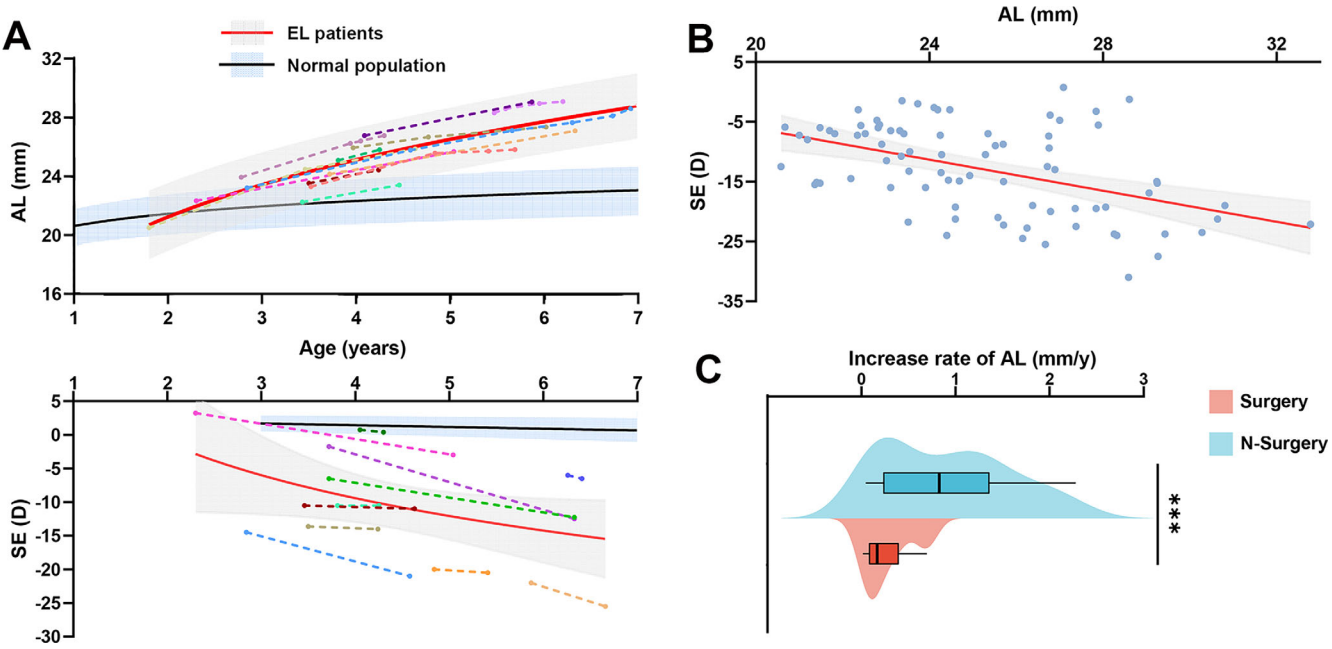

Figure 5. The changes in AL and SE in patients with EL. (**A**) The development of AL and SE in preschool children with EL and normal children with age. The *dotted lines* shown in different colors present different individuals with EL, and the *red line* presents the fitting curve of all patients. (**B**) The correlation between AL and SE ($R = -0.441$, $P < 0.0001$). (**C**) Comparison of the increased rate of AL in patients without surgery (N-Surgery) to those with surgery. ***$P < 0.001$.

the *FBN1* group, worse BCVA and earlier onset age were observed in patients in the *ADAMTSL4* group and other genes (all $P < 0.05$). Patients in the *FBN1* group and *ADAMTSL4* group were found to have a longer AL than those in other genes (all $P < 0.05$). Intriguingly, the direction of lens dislocation differed among different genes. As shown in Figure 7C, in the *FBN1* group, the lens tended to dislocate in the nasal-superior direction. In the *ADAMTSL4* group, the temporal direction was more common. For the other genes, the lens was more likely to displace downward.

For *ADAMTSL4* -associated EL, the iris anomalies were more prevalent in patients with truncation and truncation variants (T+T) ($P < 0.01$, Supplementary Fig. 2A). The early-onset (EO) cataract was more common in patients with missense and missense variants (M+M) but did not show a significant difference among different genotypes. It was observed that individuals of EA ethnicity were more likely to have an EO cataract ($P < 0.05$, Supplementary Fig. 2B).

Discussion

Currently, over 3000 variants in the *FBN1* gene have been reported in the literature, most of which has focused on its associations with cardiovascular, skeletal, or other systemic disorders.[31,32] However, comprehensive insights from an ophthalmic perspective to explore the development of ocular states are relatively limited and lack concrete genotype–phenotype correlations. Furthermore, other EL-associated genes have not been given sufficient attention due to the relatively rare occurrence. This study, based on an in-house cohort of 156 EL families, aimed to bridge these gaps with the combination of a comprehensive literature review on all EL-associated genes.

In the comparative analysis, it was observed that the proportion of both cys-disappear and cys-appear variants in the *FBN1* gene in our EL cohort was much higher than previously reported. It is widely known that cys-disappear variants have a detrimental effect on the disulfide bridges, which covalently connect three pairs of cysteine residues that are highly conserved in EGF domains,[25] whereas the missense variants resulting in cys-appear have not drawn enough attention and lack detailed analysis. The cys-appear variants introduce additional cysteine residues, also leading to misfolding of the EGF domain and damaging the structure stability of fibrillin 1 in turn.[33] The higher proportion of cys-involvement variants in our cohort may be attributed to the fact that the main symptoms of recruited probands were EL, rather than other systemic symptoms. Additionally, the diagnosis age was much earlier in our EL cohort than in the published literature. This observation further confirms that the ocular symptoms develop earlier than systemic symptoms to help early recognition and diagnosis. Therefore, our findings emphasize that the variants introducing a new and supernumerary cysteine could disturb correct disulfide bonding to cause disease occurrence. This point may have been neglected in previous studies, but further functional studies are still needed.

This study also provided valuable insights into the changes of ocular manifestations with disease progression. The results revealed that the underlying lens dislocation might initially present as lenticular-related refractive myopia at an early stage of disease but gradually convert to axial myopia with fundus changes during the progressive dislocation of the lens. Accordingly, the higher rate of AL in patients without surgery also indicated that the displaced lens leads to defocusing and deprivation, ultimately contributing to the elongation of the AL, and surgical intervention may have a beneficial effect.[34] This observation aligns with previous studies. Children with EL had slower AL change after surgery, as He et al.[35] demonstrated, and an experimental

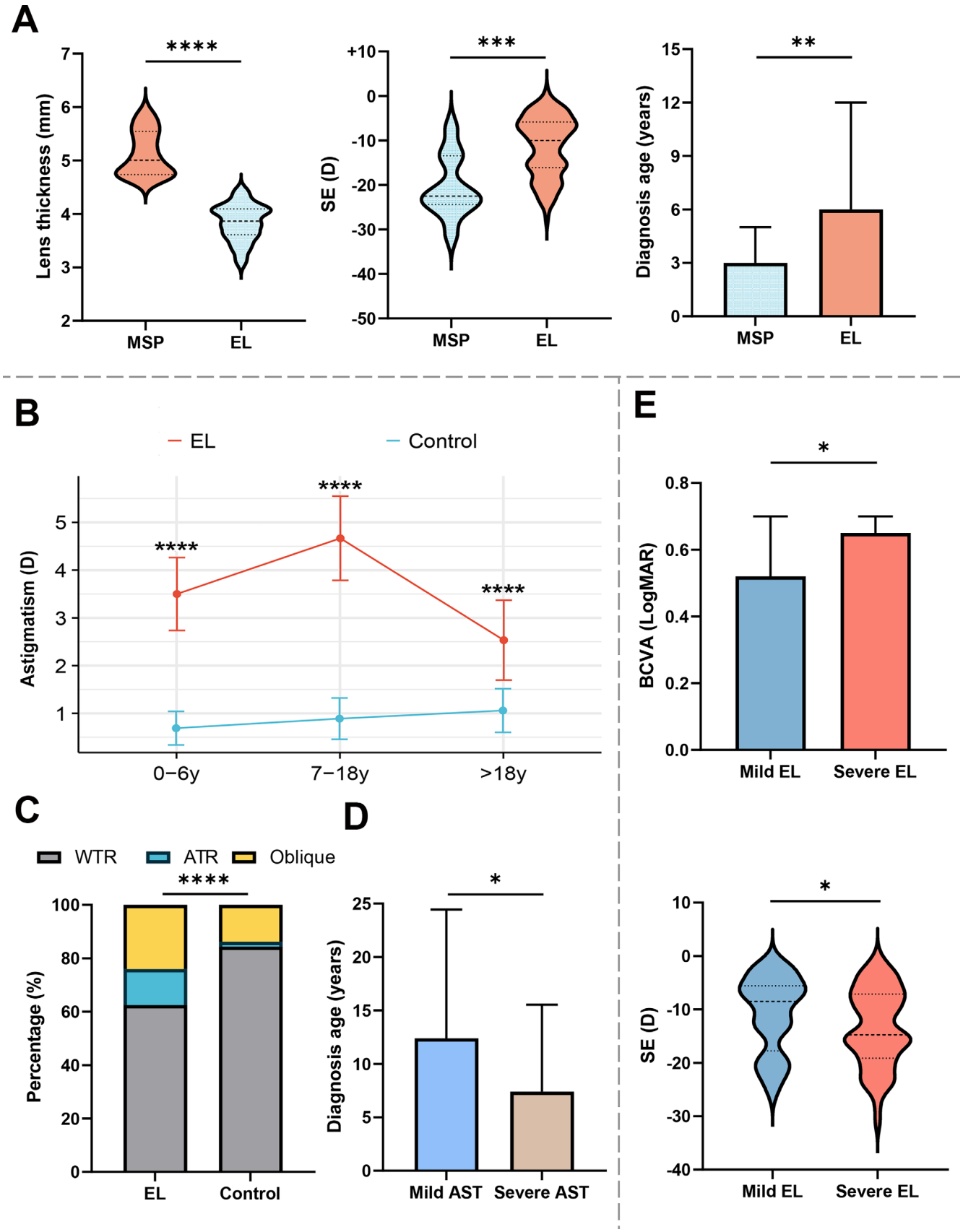

Figure 6. The clinical phenotypes of microspherophakia (MSP), astigmatism, and different severities of EL. (**A**) The difference of lens thickness, SE, and diagnosis age in the MSP group and EL group. (**B**)The degree of astigmatism in the EL cohort compared to the normal population. (**C**) The proportion of different types of astigmatism axis in the EL cohort compared to the normal population. (**D**) The diagnosis age in different severities of AST. (**E**) Comparison of BCVA and SE in different severities of EL. AST, astigmatism; ATR, against-the-rule. *$P < 0.05$, **$P < 0.01$, ***$P < 0.001$, ****$P < 0.0001$.

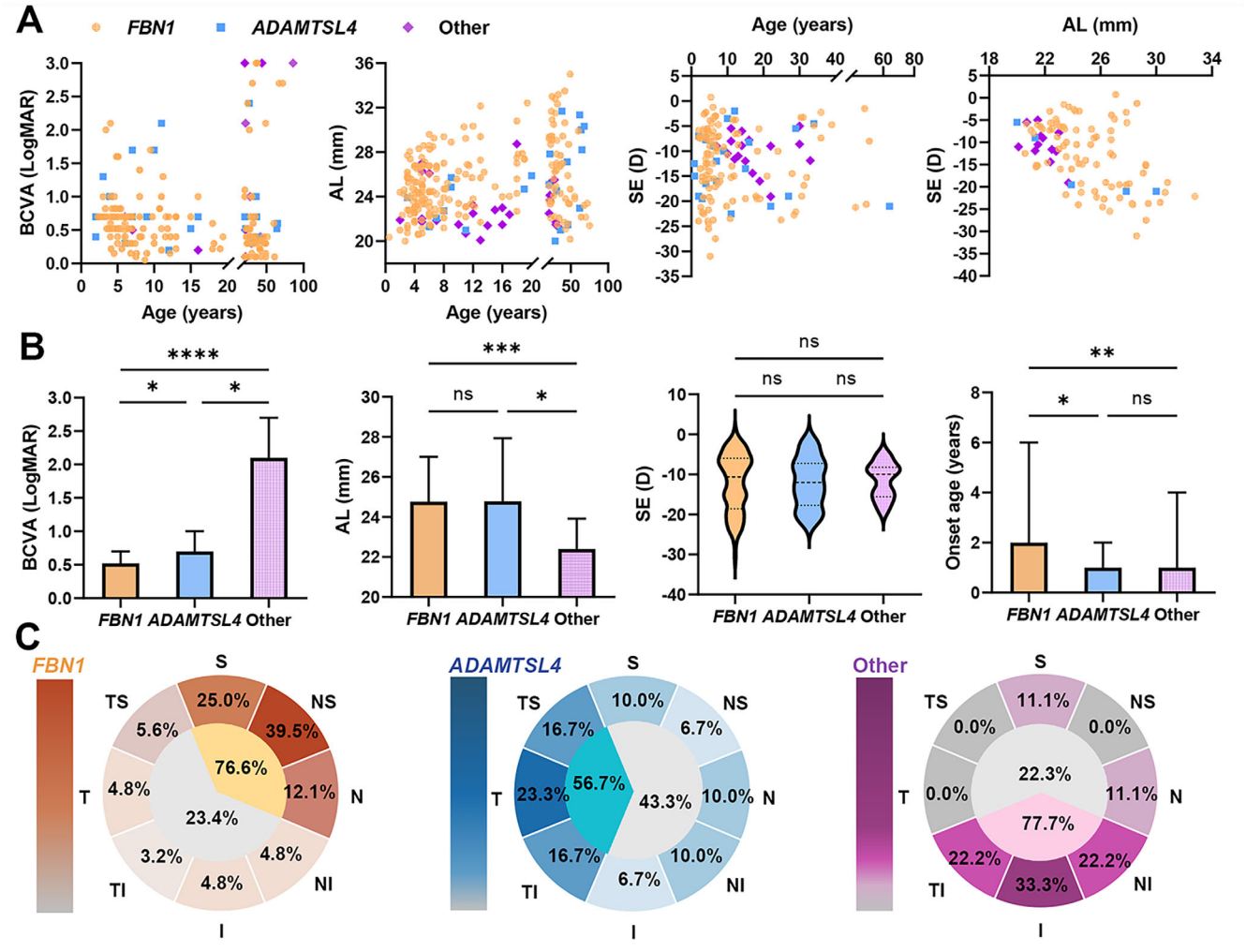

Figure 7. Comparing clinical phenotypes among different EL-associated genes by literature review and in-house data sets analysis. (**A**) The scatterplot of BCVA, AL, and SE in different EL-associated genes. (**B**) The clinical phenotypes, including BCVA, AL, SE, and onset age, were different in different EL-associated genes. (**C**) The direction of lens dislocation in different genes. I, inferior; N, nasal; NI, nasal-inferior; NS, nasal-superior; S, superior; T, temporal; TI, temporal-inferior; TS, temporal-superior.

study also showed that the conditional deletion of Fbn1 in mice resulted in a significant increase in globe size.[36] The associations between myopia and eye growth have been widely investigated, known as lens-induced myopia (LIM)[37] and form deprivation myopia (FDM).[38] The development of myopia in *FBN1*-associated EL might be closely related to both LIM and FDM mechanisms. Thus, lentectomy may be taken into consideration early before the development of axial myopia, to prevent the attendant risks such as retinal detachment and functional amblyopia.[39]

In addition, the posterior segment ocular abnormalities need to be fully evaluated, as fundus lesions were found in over 30% of cases. The occurrence of retinopathies is attributed to various factors. The myopia-related fundus caused by pathologic myopia can lead to progressive damage to the retina. Additionally, the instability of a dislocated lens exerts traction on the vitreous base, potentially causing tears or holes in the retinal periphery, which can be missed on routine examinations on account of poor visualization secondary to small pupils and lens dislocation.[40] Hence, it is essential to conduct regular and comprehensive fundus examinations after pupil dilation to identify and manage the fundus abnormalities promptly.

Intriguingly, diverse phenotypes were observed in patients with different genotypes. Patients with variants in non-*FBN1* genes had early onset and severe ocular phenotypes. This observation may be attributable to the distinct iris abnormalities and early-onset cataract in *ADAMTSL4*-associated EL, which have been described by our team.[41] Besides, microspherophakia complicated with glaucoma or intraocular hypertension was relatively common in the other genes. These severe complications can serve as warning signs that aid in the early recognition of EL and prompt appropriate management. Moreover, the direction of lens dislocation is distinctive in different genes. Thus, our results aid in differential diagnosis and guide the appropriate treatment management for different subtypes of EL.

The findings of this study should be evaluated within its limitations. First, it was a study within a single center, and the patients mainly came from the southeast of China. Second, our results depicted the overall ophthalmic features of patients with EL, while systemic symptoms also are in

Table 2. Genotype and Clinical Phenotype in *FBN1*-Associated EL

	N Region	Middle Region	C Region	P	Truncation	Missense	P	Cys-Missense	Non-Cys-Missense	P
Age (y)	6.6 (4.6–21.3)	8.9 (4.2–25.5)	8.5 (4.9–18.9)	0.794	6.7 (4.0–18.4)	8.0 (4.6–21.1)	0.511	7.3 (4.9–20.5)	10.9 (4.3–27.2)	0.150
SE (D)	−12.5 (−17.2 to −6.5)	−9.3 (−19.5 to −4.9)	−10.0 (−20.6 to −7.0)	0.816	−13.3 (−21.7 to −13.3)	−10.5 (−16.3 to −6.0)	0.377	−10.6 (−18.6 to −6.5)	−7.5 (−15.6 to −7.5)	0.585
Astigmatism (D)	3.5 (2.5–5.0)	3.0 (2.0–4.9)	4.3 (2.1–5.9)	0.326	3.0 (1.4–5.1)	3.5 (2.3–5.0)	0.390	3.9 (2.3–5.1)	3.0 (2.2–4.8)	0.596
BCVA (LogMAR)	0.7 (0.4–0.7)	0.5 (0.3–0.7)	0.5 (0.3–0.7)	0.076	0.5 (0.4–0.7)	0.6 (0.3–0.7)	0.673	0.6 (0.4–0.7)	0.5 (0.3–0.7)	0.336
AL (mm)	25.6 (23.5–27.0)	24.7 (22.8–27.0)	28.5 (24.3–30.8)	0.038	25.7 (23.7–28.8)	25.6 (23.4–27.3)	0.266	25.7 (23.7–27.5)	24.8 (22.6–26.9)	0.047
K (D)	40.8 (39.0–42.2)	41.4 (40.9–42.8)	39.9 (39.3–41.5)	0.033	41.1 (39.9–42.6)	41.0 (39.2–42.2)	0.367	40.9 (39.2–42.2)	41.3 (39.2–42.2)	0.116
LT (mm)	4.0 (3.7–4.2)	4.0 (3.5–4.6)	4.0 (3.8–4.7)	0.947	4.5 (3.9–4.9)	4.0 (3.6–4.2)	0.082	4.0 (3.7–4.4)	3.7 (3.4–4.1)	0.554

Values are presented as median (inter-quartile range).

need of attention. Hence, a longitudinal study with a larger cohort is required. Functional studies are expected to validate and understand the underlying mechanisms of the genotype–phenotype associations.

In conclusion, this study provided the clinical and genetic landscape of EL based on a cohort of 156 families. It extended the mutation spectrum of EL-associated genes for the Chinese population and highlighted the crucial role of cys-appear variants. We also provided additional insights into the changes in ocular status. Concerns need to be raised about the patients with variants in non-*FBN1* genes owing to their early onset and severe phenotypes. The knowledge gained from this study can serve as a valuable reference for early diagnosis and differential diagnosis, enabling personalized management strategies for EL.

Acknowledgments

The authors thank all patients with ectopia lentis and their guardians for their participation, which made the study possible.

Supported by the National Natural Science Foundation of China (81770965), the Science and Technology Planning Projects of Guangzhou (202102010271), and the Fundamental Research Funds of the State Key Laboratory of Ophthalmology. The sponsor or funding organization had no role in the design or conduct of this research.

Disclosure: **D. Guo**, None; **S. Li**, None; **X. Xiao**, None; **Y. Jiang**, None; **Y. Wang**, None; **G. Jin**, None; **J. Wang**, None; **J. Ouyang**, None; **X. Jia**, None; **W. Sun**, None; **P. Wang**, None; **D. Zheng**, None; **Q. Zhang**, None

References

1. Fuchs J, Rosenberg T. Congenital ectopia lentis. A Danish national survey. *Acta Ophthalmol Scand*. 1998;76:20–26.
2. Chandra A, Charteris D. Molecular pathogenesis and management strategies of ectopia lentis. *Eye (London, England)*. 2014;28:162–168.
3. Judge D, Dietz H. Marfan's syndrome. *Lancet (London, England)*. 2005;366:1965–1976.
4. Chen T-H, Chen Z-X, Zhang M, et al. Combination of panel-based next-generation sequencing and clinical findings in congenital ectopia lentis diagnosed in Chinese patients. *Am J Ophthalmol*. 2022;237:278–289.
5. Sadiq M, Vanderveen D. Genetics of ectopia lentis. *Semin Ophthalmol*. 2013;28:313–320.
6. Marzin P, Rondeau S, Alessandri JL, et al. Weill-Marchesani syndrome: natural history and genotype-phenotype correlations from 18 news cases and review of literature. *J Med Genet*. 2023;0:1–8.
7. Rahman M, Sharma M, Aggarwal P, Singla S, Jain N. Homocystinuria and ocular complications—a review. *Indian J Ophthalmol*. 2022;70:2272–2278.
8. Nelson L, Maumenee I. Ectopia lentis. *Surv Ophthalmol*. 1982;27:143–160.
9. Kulkarni N, Lloyd IC, Ashworth J, Biswas S, Black GCM, Clayton-Smith J. Traboulsi syndrome due to ASPH mutation: an under-recognised cause of ectopia lentis. *Clin Dysmorphol*. 2019;28:184–189.
10. Patel N, Khan AO, Mansour A, et al. Mutations in ASPH cause facial dysmorphism, lens dislocation, anterior-segment abnormalities, and spontaneous filtering blebs, or Traboulsi syndrome. *Am J Hum Genet*. 2014;94:755–759.

11. Jones G, Johnson K, Eason J, et al. Traboulsi syndrome caused by mutations in ASPH: an autosomal recessive disorder with overlapping features of Marfan syndrome. *Eur J Med Genet*. 2022;65:104572.
12. Van Hoorde T, Nerinckx F, Kreps E, et al. Expanding the clinical spectrum and management of Traboulsi syndrome: report on two siblings homozygous for a novel pathogenic variant in ASPH. *Ophthalmic Genet*. 2021;42:493–499.
13. Khan AO, Aldahmesh MA, Mohamed JY, Al-Mesfer S, Alkuraya FS. The distinct ophthalmic phenotype of Knobloch syndrome in children. *Br J Ophthalmol*. 2012;96:890–895.
14. Cheong SS, Hentschel L, Davidson AE, et al. Mutations in CPAMD8 cause a unique form of autosomal-recessive anterior segment dysgenesis. *Am J Hum Genet*. 2016;99:1338–1352.
15. Lin Y, Gao H, Zhu Y, et al. Two paired box 6 mutations identified in Chinese patients with classic congenital aniridia and cataract. *Mol Med Rep*. 2018;18:4439–4445.
16. Khan AO, Aldahmesh MA, Noor J, Salem A, Alkuraya FS. Lens subluxation and retinal dysfunction in a girl with homozygous VSX2 mutation. *Ophthalmic Genet*. 2015;36:8–13.
17. Braverman AC, Blinder KJ, Khanna S, Willing M. Ectopia lentis in Loeys-Dietz syndrome type 4. *Am J Med Genet A*. 2020;182:1957–1959.
18. Couser NL, McClure J, Evans MW, Haines NR, Burden SK, Muenzer J. Homocysteinemia due to MTHFR deficiency in a young adult presenting with bilateral lens subluxations. *Ophthalmic Genet*. 2017;38:91–94.
19. Wang Q, Wang P, Li S, et al. Mitochondrial DNA haplogroup distribution in Chaoshanese with and without myopia. *Mol Vis*. 2010;16:303–309.
20. Li J, Jiang D, Xiao X, et al. Evaluation of 12 myopia-associated genes in Chinese patients with high myopia. *Invest Ophthalmol Vis Sci*. 2015;56:722–729.
21. Wang P, Li S, Sun W, et al. An ophthalmic targeted exome sequencing panel as a powerful tool to identify causative mutations in patients suspected of hereditary eye diseases. *Transl Vis Sci Technol*. 2019;8:21.
22. Richards S, Aziz N, Bale S, et al. Standards and guidelines for the interpretation of sequence variants: a joint consensus recommendation of the American College of Medical Genetics and Genomics and the Association for Molecular Pathology. *Genet Med*. 2015;17:405–424.
23. Li J, Jia X, Li S, Fang S, Guo X. Mutation survey of candidate genes in 40 Chinese patients with congenital ectopia lentis. *Mol Vis*. 2014;20:1017–1024.
24. Guo D, Jin G, Zhou Y, et al. Mutation spectrum and genotype-phenotype correlations in Chinese congenital ectopia lentis patients. *Exp Eye Res*. 2021;207:108570.
25. Faivre L, Collod-Beroud G, Loeys BL, et al. Effect of mutation type and location on clinical outcome in 1,013 probands with Marfan syndrome or related phenotypes and FBN1 mutations: an international study. *Am J Hum Genet*. 2007;81:454–466.
26. Guo X, Fu M, Ding X, Morgan IG, Zeng Y, He M. Significant axial elongation with minimal change in refraction in 3- to 6-year-old Chinese preschoolers: the Shenzhen Kindergarten Eye Study. *Ophthalmology*. 2017;124:1826–1838.
27. Mutti DO, Mitchell GL, Jones LA, et al. Axial growth and changes in lenticular and corneal power during emmetropization in infants. *Invest Ophthalmol Vis Sci*. 2005;46:3074–3080.
28. Chen Y, Wang W, Wang J, et al. Normal range of ocular biometry in healthy children: a systemic review and meta-analysis of 33,559 individuals under seven years of age. *Ophthalmic Physiol Opt*. 2022;42:1264–1275.
29. Wang SK, Guo Y, Liao C, et al. Incidence of and factors associated with myopia and high myopia in Chinese children, based on refraction without cycloplegia. *JAMA Ophthalmol*. 2018;136:1017–1024.
30. Wang J, Cheng QE, Fu X, et al. Astigmatism in school students of eastern China: prevalence, type, severity and associated risk factors. *BMC Ophthalmol*. 2020;20:155.
31. Franken R, Teixido-Tura G, Brion M, et al. Relationship between fibrillin-1 genotype and severity of cardiovascular involvement in Marfan syndrome. *Heart*. 2017;103:1795–1799.
32. Stark V, Hensen F, Kutsche K, et al. FBN1 genotype-phenotype correlation in children: the impact of variants on pediatric Marfan care. *Genes*. 2020;11(7):799.
33. Schrijver I, Liu W, Brenn T, Furthmayr H, Francke U. Cysteine substitutions in epidermal growth factor-like domains of fibrillin-1: distinct effects on biochemical and clinical phenotypes. *Am J Hum Genet*. 1999;65:1007–1020.
34. Pardue MT, Stone RA, Iuvone PM. Investigating mechanisms of myopia in mice. *Exp Eye Res*. 2013;114:96–105.
35. He J, Lian Z, Cao Q, et al. Longitudinal changes of axial length and associated factors in congenital ectopia lentis patients. *J Ophthalmol*. 2022;2022:4032283.
36. Jones W, Rodriguez J, Bassnett S. Targeted deletion of fibrillin-1 in the mouse eye results in ectopia lentis and other ocular phenotypes associated with Marfan syndrome. *Dis Model Mech*. 2019;12:dmm037283.
37. Meyer C, Mueller MF, Duncker GI, Meyer HJ. Experimental animal myopia models are applicable to human juvenile-onset myopia. *Surv Ophthalmol*. 1999;44(suppl 1):S93–S102.
38. Wiesel TN, Raviola E. Increase in axial length of the macaque monkey eye after corneal opacification. *Invest Ophthalmol Vis Sci*. 1979;18:1232–1236.
39. Romano PE, Kerr NC, Hope GM. Bilateral ametropic functional amblyopia in genetic ectopia lentis: its relation to the amount of subluxation, an indicator for early surgical management. *Binocul Vis Strabismus Q*. 2002;17:235–241.
40. Remulla JF, Tolentino FI. Retinal detachment in Marfan's syndrome. *Int Ophthalmol Clin*. 2001;41:235–240.
41. Guo D, Yang F, Zhou Y, et al. Novel ADAMTSL4 gene mutations in Chinese patients with isolated ectopia lentis. *Br J Ophthalmol*. 2023;107:774–779.